

Renal sarcoidosis and hypercalcaemia

O.P. Sharma

Correspondence: O.P. Sharma, Room 11-900, Los Angeles County-University of Southern California Medical Center, 1200 North State Street, Los Angeles, CA 90033, USA. Fax: 1 3232262728; E-mail: osharma@usc.edu

Although the kidneys are infrequently involved in sarcoidosis, physicians involved in taking care of sarcoidosis patients need to be aware of this possibility in order to diagnose and treat this dangerous disorder before it causes serious damage. Sarcoidosis may either involve the kidneys directly or cause renal failure secondary to hypercalcaemia, hypercalciuria and nephrocalcinosis.

Hypercalcaemia is an important complication of sarcoidosis. It is caused by overproduction of 1,25-dihydroxyvitamin D₃ (calcitriol or calcitriol) by activated macrophages and the granulomatous tissue. Calcitriol, in turn, causes increased absorption of calcium from the gut. Hypercalcaemia is not specific to sarcoidosis as it is found in other granulomatous, as well as nongranulomatous, disorders, including tuberculosis, coccidioidomycosis, histoplasmosis, leprosy and Wegener's granulomatosis.

Renal sarcoidosis

Incidence

Clinically manifest renal involvement is rare in sarcoidosis [1–3]. In A Case–Control Etiologic Study of Sarcoidosis (ACCESS), clinical involvement of the kidneys was observed in only 0.7% of patients (table 1) [4], although as many as 20% of patients with sarcoidosis show granulomas in the kidneys [5–8]. Autopsy studies in Japanese patients reveal an incidence of 26% [9]. BERGENER *et al.* [10] diagnosed 46 patients with sarcoidosis between 1995 and 2002. Fifteen (32%) of these patients exhibited renal abnormalities, of whom 10 underwent kidney biopsy. Six patients exhibited nephrocalcinosis, of whom two showed granulomatous interstitial nephritis, one interstitial nephritis without granuloma and one immunoglobulin (Ig) A glomerulonephritis. In two patients, they found a combination of granulomatous interstitial nephritis with either nephrocalcinosis or IgA glomerulonephritis. Renal involvement was present only in patients with chronic

Table 1. – Organ involvement in sarcoidosis

First author [Ref.]	Scope	Organ involvement %										
		Lungs	Skin (chronic)	EN	LN/ spleen	Eye	Liver	NS	Cardiac	Spleen	Ca ²⁺ metab	Renal
SILTZBACH [1]	World	87	9	17	28	NA	NA	4	NA	NA	11	NA
JAMES [3]	UK [#]	88	18	34	39	27	10	9	3	12	18	1
BAUGHMAN [4]	ACCESS	95	15.9	8.3	11.8	11.5	8.3	4.6	2.3	4.6	3.7	0.7

EN: erythema nodosum; LN: lymph node; NS: nervous system; metab: metabolism; ACCESS: A Case–Control Etiologic Study of Sarcoidosis; NA: not available. [#]: Royal Northern Hospital, London, UK (now closed).

sarcoidosis, whereas patients with Lofgren's syndrome showed no renal involvement [10]. The renal involvement may be the initial manifestation of sarcoidosis, may appear during the course of the illness or follow the onset of the disease after many years. Occasionally, chronic hypercalcaemia or nephrolithiasis may be the only presenting feature of renal sarcoidosis [11].

Diagnosis

The criteria for establishing the diagnosis of sarcoidosis are: 1) compatible clinical or radiographic evidence of multisystemic involvement; 2) histological evidence of noncaseating granuloma (fig. 1); and 3) negative results from special stains, cultures and serological studies for other entities (e.g. absence of acid-fast bacilli or fungi in sputum, body fluids or tissue biopsy specimens; negative complement fixation test results for coccidioidomycosis, histoplasmosis and brucellosis; and negative PCR for Whipple's disease) [12]. A diagnosis based on only one of these features is misleading since clinical or radiological manifestations present too wide a spectrum of differential diagnoses, whereas noncaseating granulomas may be caused by bacteria, fungi, viruses and chemical agents. Occasionally, lymphoma and malignancy can also generate a granulomatous reaction [13].

Clinical features

Renal disease in sarcoidosis may be divided into the following clinical categories (table 2).

Granulomatous interstitial nephritis. Although 20% of patients with sarcoidosis may show granulomas in the kidneys, development of the clinical syndrome of granulomatous interstitial nephritis is unusual. UTAS *et al.* [14] described a patient who had developed mild proteinuria. Creatinine clearance was $60 \text{ mL} \cdot \text{min}^{-1}$, renal biopsy showed typical noncaseating granulomas with normal glomeruli, chest radiography and gallium scan results were normal, and the patient exhibited uveitis. Thus, the patient most probably had sarcoidosis. Nevertheless, in a review of 1,010 renal biopsy procedures, SCHWARZ

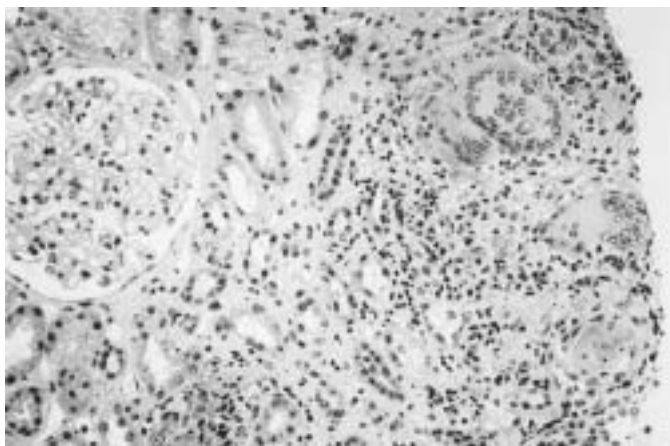


Fig. 1. – Renal biopsy specimen showing noncaseating granulomas with many multinucleate giant cells (haematoxylin-eosin stain).

Table 2. – Types of renal involvement in sarcoidosis

Granulomatous interstitial nephritis
Glomerulonephritis
IgA nephropathy (Berger's disease and glomerular disease)
Renal cell carcinoma
Granulomatous vasculitis or renal angiitis
Nephrocalcinosis and nephrolithiasis

Ig: immunoglobulin.

et al. [15] found only six instances of granulomatous interstitial nephritis, all of which were caused by drugs; none were related to sarcoidosis. In another study of 76 cases of granulomatous nephritis, drugs were the main causative agent [16].

MARIE *et al.* [17] described a 60-yr-old male with diffuse joint pains, albuminuria and haematuria. Serum angiotensin-converting enzyme (SACE) and autoantibody screening results were normal. A renal biopsy specimen showed interstitial and granulomatous nephritis; direct immunofluorescence and Ziehl-Nelson test results were negative. Abdominal and thoracic computed tomography, echocardiography, and accessory salivary gland and duodenum biopsy results were normal. Despite corticosteroid therapy, the patient's renal function and general condition deteriorated. Biopsy of the ileum revealed the changes of Whipple's disease, and PCR analysis of ribosomal RNA demonstrated the presence of *Tropheryma whipplei* [17]. This patient not only showed no clinical or radiological evidence of sarcoidosis but also failed to respond to corticosteroids. This unusual presentation necessitated further evaluation, which confirmed the presence of a rare illness. This case shows that, if all of the criteria recommended for diagnosing sarcoidosis are not met, a diagnostic error is likely to appear.

MANES *et al.* [18] described a 59-yr-old male with acute renal failure, hypercalcaemia, anaemia and unilateral facial nerve palsy. Renal biopsy revealed interstitial granulomatous nephritis. Corticosteroid therapy produced normalisation of calcium level, recovery of renal failure and disappearance of 7th cranial nerve paralysis. In this patient, renal failure appeared with the advent of other manifestations of sarcoidosis, and the patient responded accordingly.

Glomerulonephritis. The histological changes of focal segmental sclerosis, membranous glomerulonephritis, mesangioproliferative glomerulonephritis, IgA nephropathy and crescentic glomerulonephritis have been described sporadically. Most such patients have either proteinuria or clinical nephrotic syndrome. Hypertension occurs frequently but is rarely a serious problem.

Membranous glomerulonephritis (nephropathy) associated with nephrotic syndrome has been seen in sarcoidosis. Renal biopsy shows membranous nephropathy with or without granulomas, and electron microscopy may reveal typical subepithelial deposits. Corticosteroids are effective [19–22]. Glomerular involvement is rare. The mechanism of glomerular injury is not known, but IgG and complement deposits have been observed [23]. In one patient with crescentic glomerulonephritis and granulomas, antineutrophilic cytoplasmic antibodies were observed [24]. In another patient with granulomatous glomerulonephritis, the diagnosis of Wegener's granulomatosis was entertained [25]. These patients do not satisfy the diagnostic criteria for sarcoidosis and most probably represent cases of vasculitis.

Immunoglobulin A nephropathy (Berger's disease) and glomerular disease. Membranous and proliferative glomerular abnormalities have both been described in sarcoidosis. In 1968 in France, BERGER and HINGLAIS [26] first described IgA nephropathy. The histological picture is characterised by mesangial deposition of IgA,

variable amounts of complement component 3, IgM and IgG associated with mesangial proliferative glomerulonephritis. Although the cause remains unknown, clinical exacerbations usually follow a viral illness. TAYLOR and ANSELL [27] reported a sarcoidosis patient with IgA nephropathy and nephrotic syndrome. NISHIKI *et al.* [28] observed a similar patient who also had thyroiditis. Both of these patients responded to corticosteroid therapy. SCHMIDT *et al.* [29] described the case of a 39-yr-old male who developed end-stage renal failure due to IgA nephropathy and received a renal transplant. After 17 months, the patient developed a massive pleural effusion and finger clubbing. Lung and pleural biopsy revealed noncaseating granulomas. He responded to corticosteroids [29]. HAMADA *et al.* [30] reported one definite and two subclinical cases of IgA nephropathy during the course of sarcoidosis. These anecdotal studies, however, do not reveal the precise incidence of, or nature of, the relationship between sarcoidosis and IgA nephropathy. It is not usual practice to obtain renal biopsy specimens from patients with sarcoidosis unless renal function is severely impaired; hence, the incidence of subclinical nephropathy remains unknown.

Renal carcinoma and sarcoidosis. It is well known that sarcoid granulomas may be found in regional lymph nodes draining carcinomas or lymphomas. Granulomas have also been found in cancerous or lymphomatous tissue. This local or limited granulomatous response should not be confused with multisystemic sarcoidosis (table 3). Occasionally, a neoplasm, particularly renal, testicular or breast, may produce bilateral hilar adenopathy. Rarely, sarcoidosis and cancer may coexist in the same patients. By applying strict diagnostic criteria, most reported cases can be separated into a local granulomatous reaction and multisystemic sarcoidosis.

A 53-yr-old male was found to have microalbuminuria. His serum creatinine level was 1.4 mg·dL⁻¹. Renal biopsy showed a perivascular granuloma and renal ultrasonography suggested renal cell carcinoma. At operation, a papillary adenocarcinoma of the right kidney was found. The rest of the kidney was normal, except for a small granulomatous lesion, on histological examination. The chest radiograph and SACE and calcitriol levels were normal. This represents a localised sarcoid reaction to renal cancer and not systemic sarcoidosis [31]. MARINIDES *et al.* [32] described a patient with a renal papillary adenocarcinoma and associated granulomatous reaction in the same kidney. Hypernephroma has also been described as causing or coexisting with a granulomatous response similar to sarcoidosis [33–35].

Table 3. – Differences between a nonspecific local sarcoid reaction due to a cancer and multisystemic sarcoidosis

	Local sarcoid reaction	Multisystemic sarcoidosis
Organ involvement	Usually one	More than one
Age yrs	Any	20–50
Chest radiograph	Usually normal or atypical with unilateral involvement	Abnormal in 90% and typical for sarcoidosis
HRCT	May suggest cancer	May suggest sarcoidosis
Elevated SACE %	<5	>60
Kveim–Siltzbach test	Negative	Positive
BALF lymphocytes	Absent	Present
Slit-lamp examination	Normal	Positive in 15–20%
Hypercalcaemia	May be present in some cancers	Present in 13%
Whole-body gallium scan	Localised uptake	Multisystemic uptake

HRCT: high-resolution computed tomography; SACE: serum angiotensin-converting enzyme; BALF: bronchoalveolar lavage fluid.

Granulomatous vasculitis. Although hyaline deposits in arterial walls occur frequently in sarcoidosis, true obliterative granulomatous involvement of the renal arteries is uncommon. When it occurs, it is usually associated with severe hypertension and carries a poor prognosis.

Hypercalciurialnephrocalcinosis. Persistent hypercalciuria may lead to nephrocalcinosis, renal stones with obstruction of the collecting tubules and finally renal failure. Renal stones were the presenting feature of sarcoidosis in 3.6% of 110 consecutive Italian patients with histologically proven sarcoidosis, followed by RIZZATO *et al.* [2] at a sarcoidosis clinic in Milan, Italy. HAMADA *et al.* [30] found renal impairment mostly in patients with hypercalcaemia, but nephrocalcinosis was not found in all cases.

Vitamin D and calcium metabolism

Vitamin D is both a hormone and a vitamin. The prohormone vitamin D₃ is produced in the skin through the effect of ultraviolet light (ultraviolet B) and transported to the liver, where it is hydroxylated to 25-hydroxyvitamin D₃, which, in turn, is hydroxylated in the kidney to form the most active metabolite of vitamin D, calcitriol. Its production in the kidney is closely regulated by parathyroid hormone and serum phosphate. Calcitriol functions like a steroid hormone by binding to specific receptors and initiating the gene transcription of various proteins. Its binding to specific receptors in the intestine and generation of calcium-binding proteins increases calcium absorption. Calcitriol, by binding to specific receptors in bone cells, stimulates osteoblasts to make osteocalcin, the specific protein involved in bone mineralisation and differentiation of stem cells in the bone marrow. It increases the formation of osteoclasts involved in bone resorption. Calcitriol influences the differentiation of cells in the haematopoietic system, and T- and B-lymphocyte function. It inhibits proliferation of cancer cells.

Synthesis and source of 1,25-dihydroxyvitamin D₃

The most active metabolite of vitamin D, calcitriol, is produced in the kidney from 25-hydroxycholecalciferol (25-(OH)D₃), which is produced in the liver. BELL *et al.* [36] reported that, in three sarcoidosis patients with hypercalcaemia, plasma levels of calcitriol were high when calcium levels were raised and fell when calcium levels returned to normal either spontaneously or after prednisone therapy. Further evidence that abnormally high levels of calcitriol occur in hypercalcaemic sarcoidosis patients was provided by MITCHELL *et al.* [37], who reported a 28-yr-old female with hypoparathyroidism who had required vitamin D therapy since the age of 19 yrs. She developed sarcoidosis and became hypercalcaemic. On cessation of vitamin D therapy, her calcium levels returned to normal, but the administration of hydrocortisone caused hypocalcaemia. Her plasma calcitriol level was three times the highest level recorded in a patient with hypoparathyroidism undergoing treatment with vitamin D [37]. Another patient studied by ZIMMERMAN *et al.* [38] had hypoparathyroidism but was able to discontinue vitamin D treatment with maintenance of normal serum calcium levels when sarcoidosis developed. An elevated serum concentration of calcitriol, a metabolite synthesised solely in normal nonpregnant human subjects, occurred in a hypercalcaemic anephric male patient with sarcoidosis [39]. These observations support the original contention of HENNEMAN *et al.* [40] that the hypercalcaemia of sarcoidosis is a form of vitamin D intoxication and also establish that the hormone is produced at an extrarenal site. ADAMS *et al.* [41] showed that calcitriol causes hypercalcaemia in sarcoidosis and that macrophages from patients with active disease are

the synthetic source of hormone. MASON *et al.* [42] identified a similar metabolite in preparations of sarcoid granulomas incubated with calcitriol. The identity of the hormone and its origin are now known, but the question remains as to why nature bothers to produce this hormone. There has to be a reason. Albert Einstein wrote, in a letter to his friend Max Born, "I cannot believe that God would choose to play dice with the world" [43]. Is the production of calcitriol solely for the purpose of causing damage to tissue? Is it produced to protect the body from an uncontrolled wild immunological response? Of course, there is the third possibility that the hormone is a harmless by-product.

Role of 1,25-dihydroxyvitamin D₃

The following lines of evidence support an immunoregulatory role for calcitriol: 1) the presence of high-affinity intracellular receptors for calcitriol (vitamin D receptors (VDRs)) in lymphocytes, macrophages and dendritic cells [44, 45]; 2) the inhibition by calcitriol of mitogen-induced lymphocyte proliferation and immunoglobulin production [46]; 3) the reduction by calcitriol of interleukin (IL)-2 production by lymphocytes [47]; and 4) the enhancement by calcitriol of the ability of macrophages to inhibit proliferation of *Mycobacterium tuberculosis in vitro* [48, 49]. Thus, the hormonal form of vitamin D seems to possess a role similar to that of cytokines. The precise lesion that controls the abnormal regulation of calcitriol synthesis is obscure, but it may be due to a defective feedback control of calcitriol production at the site of synthesis in macrophages or in target cells for calcitriol, such as lymphocytes. Production of the hormone may, thus, be part of the normal immune response in retaliation to antigenic stimulation, and may induce secretion of other mediators. Calcitriol modulates the cytotoxic and antibody-producing functions of lymphocytes. The action depends on the threshold of VDR expression, and is mediated through inhibition of the T-cell cytokine IL-2. Calcitriol retards interferon gamma (IFN- γ) synthesis by T-cells, and this may act as part of the control of calcitriol synthesis by macrophages that produce the hormone when stimulated by IFN- γ . The inhibition of Ig production is due to direct suppression of T-helper cells or macrophages [50]. The presence of VDRs in T-cell-mediated natural killer cells indicates that calcitriol may modulate the immune response to viral and neoplastic processes [51, 52].

Hypercalcaemia

Hypercalcaemia is one of the most common biochemical abnormalities found in clinical practice. It may be discovered when serum calcium level is measured as a screening test or as part of the evaluation for fatigue, unexplained weakness, neuromuscular disability, renal stones or osteopenia. The three most common causes of hypercalcaemia are primary hyperthyroidism, granulomatous disorders and malignancy. Disturbance of vitamin D metabolism contributes to a state of disordered calcium homeostasis in these disorders. In granulomatous disorders, including sarcoidosis, Crohn's disease, tuberculosis, leprosy and coccidioidomycosis, the inappropriate endogenous overproduction of the metabolite calcitriol by activated macrophages and granulomas is responsible for hypercalcaemia and hypercalciuria.

The reported incidence of hypercalcaemia in sarcoidosis ranges 2–63% [53]. The frequency, with a few exceptions, tends to be higher in North American series; the highest, 63%, was reported by McCORT *et al.* [54]. CUMMINGS [55] found calcium levels of $>11 \text{ mg} \cdot 100 \text{ mL}^{-1}$ in 35% of patients. MAYOCK *et al.* [56], in their review of 509 patients, recorded a frequency of 17%. Only six of the 62 patients of SCADDING [57] in London, UK showed serum calcium levels of $>11.0 \text{ mg} \cdot 100 \text{ mL}^{-1}$. MATHER [58] reported a still lower prevalence: only four of 86 untreated patients with sarcoidosis exhibited

hypercalcaemia. In Finland, PUTKONEN *et al.* [59] could find only two patients with high calcium levels in a series of 60. There is no conclusive evidence that race, age, sex, occupation or geographical distribution influence the development of hypercalcaemia. Although hypercalcaemia appears to be a consistent feature, the studies showing an excessively high frequency of occurrence need to be revised. It is reasonable to accept the incidence of 11% noted by JAMES *et al.* [60] in their worldwide review of 3,676 patients with sarcoidosis. Hypercalcaemia is usually transient in subacute sarcoidosis and fluctuate and persistent in chronic sarcoidosis, depending on the activity of the disease. Furthermore, hypercalcaemia may occur only at a certain phase during the long course of chronic sarcoidosis. Consequently, to get a true picture of calcium abnormality, serum calcium levels must be measured regularly and consistently over a long period of time. It has been suggested that hypercalcaemia is more frequent during the summer months, when exposure to the sun is at its peak [61, 62]. However, this is not the case. Hypercalcaemia occurs frequently in sarcoidosis patients in London (UK), Reading (UK), New York (NY, USA) and Lisbon (Portugal). Besides, PUTKONEN *et al.* [59] found lower levels in summer months and slightly higher mean levels in late autumn.

HARRELL and FISHER [63] were the first to recognise the relationship between vitamin D and sarcoidosis. In 1939, they described the presence of hypercalcaemia in six of 11 patients with sarcoidosis. In one of their patients, serum calcium level rose from 9.6 to 14.2 mg·dL⁻¹ after consumption of cod liver oil. These authors made three pertinent clinical observations: 1) hypercalcaemia is a feature of sarcoidosis; 2) consuming a vitamin-D-rich diet results in aggravation of hypercalcaemia; and 3) vitamin D might be related to the calcium abnormality in sarcoidosis. Soon afterwards, HEMMEMAN *et al.* [40] postulated that the disordered calcium homeostasis in sarcoidosis patients was strikingly similar to that seen in patients with vitamin D intoxication. In 1963, TAYLOR *et al.* [64] observed that, in 345 patients with sarcoidosis in North Carolina (USA), mean serum calcium level in the winter months was 9.89 mg·dL⁻¹, but rose to 10.26 mg·dL⁻¹ in one of the present author's patients who showed a response to corticosteroids, whereas, amongst 12,027 controls, the levels during winter and summer months remained unchanged. In the two hypercalcaemic patients of DENT [65] at University College Hospital (London, UK), further rises in serum calcium level occurred after whole-body ultraviolet light irradiation. HENDRIX [66], conversely, gave two hypercalcaemic and hypercalciuric patients with sarcoidosis a vitamin D-deficient diet and shielded them from sunlight. In 8 weeks, serum calcium levels became normal, hypercalciuria subsided and faecal excretion of calcium increased. These observations strengthened the belief that the development of hypercalcaemia in sarcoidosis was due to enhanced target responsiveness to vitamin D, increasing calcium absorption in the intestine, increasing resorption in the bones and increasing excretion in the kidneys.

Clinical features

The symptoms and signs of hypercalcaemia include polyuria and polydipsia, renal colic, lethargy, anorexia, dyspepsia and peptic ulceration, constipation, depression, drowsiness and impaired cognition. Patients with malignancy and lymphomas may, in addition, complain of weight loss.

Hypercalciuria, nephrocalcinosis and renal stones

Hypercalcaemia has long been recognised as a complication of sarcoidosis, but the importance of hypercalciuria has been less thoroughly appreciated. Nevertheless, hypercalciuria is three times more common than hypercalcaemia (table 4) [67].

Hypercalciuria has been reported to be more common in males than females, and, in London (UK), in Caucasian than in West Indian patients. In patients with abnormal renal function, hypercalciuria is always present when the patient has sarcoidosis-related hypercalcaemia. The mechanism of hypercalciuria appears to be threefold: 1) absorptive, associated with elevated calcitriol levels and abnormal urinary calcium:creatinine ratio; 2) resorptive, associated with excessive dissemination of sarcoidosis, including in bones, and high SACE (osteopenia may occur and hypercalciuria persist on a calcium-poor diet); and 3) associated with osteoclast-activating factor, a bone-resorbing substance [68]. According to BROULIK *et al.* [69], the urinary excretion rate of calcium is based on the filtered load of calcium when corrected for urinary calcium excretion; the tubular maximum resorptive rate for calcium is not increased. These results suggest that calcitriol has no direct effect on renal calcium handling, and hypercalciuria is due to the flow of calcium from the gut and bone.

Treatment

The magnitude and persistence of the hypercalcaemia are the key indications for therapy. Severe hypercalcaemia, defined as a serum calcium concentration of $>14 \text{ mg}\cdot\text{dL}^{-1}$, is unusual in sarcoidosis. The goals of treatment include: 1) reduction of oral and intravenous intake of calcium supplements, dietary calcium and vitamin D; 2) maintenance of an expanded intravascular volume; 3) reduction of the inappropriate production of calcitriol by sarcoid macrophages and granulomas; and 4) reduction of calcitriol-induced intestinal calcium absorption and bone resorption.

Prednisone ($20\text{--}40 \text{ mg}\cdot\text{day}^{-1}$) is the drug of choice for reducing endogenous production of calcitriol. Corticosteroids cause a swift decrease in circulating calcitriol and serum calcium levels within 3–5 days. A decrease in urinary calcium excretion rate soon follows within 7–10 days (fig. 2). Failure to normalise serum calcium levels after 2 weeks should lead the clinician to exclude the possibility of a coexisting disorder, including hyperparathyroidism, lymphoma, carcinoma and myeloma. Once the calcium abnormality is brought under control, the prednisone dose can be reduced over a period of 4–6 weeks. Serum calcium and urinary calcium excretion rate need to be monitored frequently. If the patient develops unbearable corticosteroid side-effects or fails to respond, chloroquine or hydroxychloroquine should be given. The latter two drugs are known to reduce serum calcitriol production and serum calcium levels [70–72]. The antifungal drug ketoconazole, a known inhibitor of cytochrome P450 steroid oxidase, lowers circulating calcitriol and serum calcium levels; however, the efficacy of these drugs is not widely known [73, 74]. The patient should be instructed to avoid sunlight, curtail intake of major dietary sources of vitamin D and calcium, and drink plenty of fluids. The major sources of vitamin D are fish (sardine, salmon and cod), liver and egg yolk. In the USA and Scandinavia, dairy products are supplemented with vitamin D, and each quart of milk is fortified with 400 IU of either vitamin D₂ or D₃, but, in other countries, milk is usually not supplemented (1 quart (UK)=1.14 L; 1 quart (US, liquid)=0.946 L). These precautions should be strictly adhered to (table 5). Normocalcaemic patients with sarcoidosis may develop hypercalcaemia, renal

Table 4. – Incidence of simultaneous serum-urine calcium elevation in 75 patients with sarcoidosis

Calcium elevation site	Subjects n (%)
Serum or urine	37 (49)
Serum and urine	10 (13)
Urine alone	27 (36)
Serum alone	0 (0)

Modified from [67].

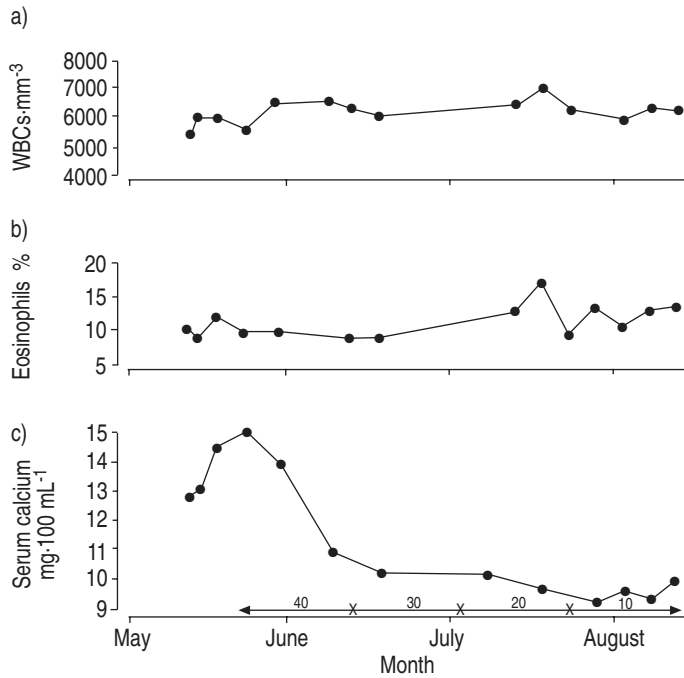


Fig. 2. – Response of hypercalcaemia to corticosteroid therapy: a) white blood cell (WBC) count, b) eosinophil density, and c) serum calcium concentration. Double-headed arrows indicate prednisone dose (milligrams-day⁻¹); x-axis corresponds to middle of each month. Response is usually quick and occurs within 1 week

stones and renal failure. Urinary stones due to persistent hypercalciuria can be pulverised by extracorporeal lithotripsy before resorting to surgery (fig. 3) [75].

Conclusion

The spectrum of sarcoidosis also encompasses renal sarcoidosis, a relatively uncommon but difficult complication of the disease. Renal disease, if diagnosed early, can be subdued with judicious use of corticosteroids, antimalarial drugs and immunosuppressive agents. Renal sarcoidosis may be primary or associated with impaired calcium metabolism. Although hypercalcaemia and hypercalciuria may both occur in sarcoidosis, the latter is approximately three times more common than the former.

Table 5. – Precautions for preventing nephrocalcinosis and stone formation in sarcoidosis

Diet	
Fluid	≥3–4 L·24 h ⁻¹
Sodium	Restrict intake
Protein	Moderate
Calcium	Avoid diets rich in vitamin D and calcium
Oxalate	Avoid oxalate-rich foods, e.g. rhubarb
Drugs	
Diuretics (thiazides)	Reduce Ca ²⁺ excretion; helpful in patients with hypercalciuria and recurrent stone formation
Allopurinol	If serum urate and urate excretion high
Vitamin D supplements	Avoid




Fig. 3. – Renal stones passed by the patient after successful extracorporeal lithotripsy: a) right kidney; and b) left kidney. Scale bar=5 mm.

Summary

The classic renal lesion of sarcoidosis is an epithelioid cell granuloma. Distinction from other diseases that may cause granulomas in the kidney, particularly renal neoplasm, can be difficult. Sarcoidosis can directly involve various structures in the kidneys, causing granulomatous nephritis, nongranulomatous nephritis and vasculitis. Therefore, the firm and final diagnosis of renal sarcoidosis depends on tissue biopsy and a clinical picture consistent with multisystemic sarcoidosis. Once the diagnosis is established, therapy includes corticosteroids, antimalarial drugs and immunosuppressive agents. Hypercalcaemia rarely causes renal failure; hypercalciuria, however, is associated with a high incidence of nephrocalcinosis. Hypercalciuria is more frequent than hypercalcaemia and may be present without hypercalcaemia, but the reverse is not true. Hypercalcaemia is always associated with hypercalciuria. Abnormalities of calcium metabolism in sarcoidosis are due to increased production of 1,25-dihydroxyvitamin D₃ (calcitriol) by sarcoid granulomas and activated macrophages.

Keywords: Angiotensin-converting enzyme, 1,25-dihydroxyvitamin D₃, hypercalcaemia, hypercalciuria, nephrocalcinosis, noncaseating granuloma.

References

1. Siltzbach L, James D, Neville E, *et al.* Course and prognosis of sarcoidosis around the world. *Am J Med* 1974; 57: 847–852.
2. Rizzato G, Palmieri G, Agrati A, *et al.* The organ-specific extrapulmonary presentation of sarcoidosis: a frequent occurrence but a challenge to an early diagnosis. *Sarcoidosis Vasc Diffuse Lung Dis* 2004; 21: 119–126.

3. Pathology. In: James D, Williams W. Sarcoidosis and other Granulomatous Disorders. Major Problems in Internal Medicine. Vol. 24. New York, NY, W.B. Saunders Company 1985; pp. 38–48.
4. Baughman R, Teirstein A, Judson M, *et al.* Clinical characteristics of patients in a case control study of sarcoidosis. *Am J Respir Crit Care Med* 2001; 164: 1885–1889.
5. Longcope W, Freiman D. A study of sarcoidosis based on a combined investigation of 160 cases including 30 autopsies from the John Hopkins Hospital and MGH. *Medicine* 1984; 31: 1–37.
6. Muther R, McCarron D, Bennett W. Renal manifestations of sarcoidosis. *Arch Intern Med* 1981; 141: 643–646.
7. Hagege A, Baglin J, Prinseau J, *et al.* Sarcoidosis disclosed by renal insufficiency (3 cases). *Sem Hop* 1983; 59: 2823–2826.
8. Guenel J, Chevet D. Interstitial nephritis in sarcoidosis. *Presse Med* 1990; 19: 1215–1217.
9. Tateno S, Kobayashi Y. Renal manifestations of sarcoidosis: a review. *Nippon Rinsho* 1994; 52: 1613–1618.
10. Bergener R, Hoffman M, Waldherr R, *et al.* Frequency of kidney disease in chronic sarcoidosis. *Sarcoidosis Vasc Diffuse Lung Dis* 2003; 20: 118–125.
11. Rizzato G, Colombo P. Nephrolithiasis as a presenting feature of chronic sarcoidosis: a prospective study. *Sarcoidosis Vasc Diffuse Lung Dis* 1996; 13: 167–172.
12. Hunninghake G, Costabel U, Ando M, *et al.* American Thoracic Society/European Respiratory Society/World Association of Sarcoidosis and Other Granulomatous Disorders: statement on Sarcoidosis. *Sarcoidosis Vasc Diffuse Lung Dis* 1999; 16: 149–173.
13. Sharma O, Lamb C. Cancer in interstitial pulmonary fibrosis and sarcoidosis. *Curr Opin Pulm Med* 2003; 9: 396–401.
14. Utas C, Dogukan A, Patriroghu T, *et al.* Granulomatous interstitial nephritis in extrapulmonary sarcoidosis. *Clin Nephrol* 1999; 51: 252–254.
15. Schwarz A, Krause P, Kunzendorf V, *et al.* The outcome of interstitial nephritis: risk factors for the transition from acute to chronic interstitial nephritis. *Clin Nephrol* 2000; 52: 179–190.
16. Schwarz A, Krause P, Keller F, *et al.* Granulomatous interstitial nephritis after non-steroidal anti-inflammatory drugs. *Am J Nephrol* ; 8: 410–416.
17. Marie I, Lecomte F, Leveque H. Granulomatous nephritis as the first manifestation of Whipple's disease. *Ann Intern Med* 2000; 132: 94–95.
18. Manes M, Molino A, Gaiter A, *et al.* Isolated renal failure secondary to sarcoidosis. *Recenti Prog Med* 2000; 91: 441–443.
19. Dimitriades C, Shetty AK, Vehaskari M, Craver RD, Gedalia A. Membranous nephropathy associated with childhood sarcoidosis. *Pediatr Nephrol* 1999; 13: 444–447.
20. Khan I, Simpson J, Catto G, *et al.* Membranous nephropathy and granulomatous interstitial nephritis in sarcoidosis. *Nephron* 1994; 66: 459–461.
21. Mundlein E, Green T, Ritz E. Graves' disease and sarcoidosis in a patient with minimal glomerulonephritis. *Nephrol Dial Transplant* 1996; 11: 860–862.
22. Parry R, Falk C. Minimal change disease associated with sarcoidosis. *Nephrol Dial Transplant* 1997; 12: 2159–2160.
23. Quismorio F, Sharma O, Chandor S. Immunopathological studies on the cutaneous lesions in sarcoidosis. *Br J Dermatol* 1977; 97: 635–642.
24. Auinger M, Irsigler K, Breiteneder S, *et al.* Normocalcemic hepato-renal sarcoidosis with crescentic glomerulonephritis. *Nephrol Dial Transplant* 1977; 12: 1474–1477.
25. Ahuja T, Mattana J, Valerraman E, *et al.* Wegener's granulomatosis followed by development of sarcoidosis. *Am J Kidney Dis* 1996; 28: 893–898.
26. Berger J, Hinglais N. *Les depots intracapillaire d'IgA-IgG. [Intra-capillary deposits of IgA and IgG]. J Urol Nephrol (Paris)* 1968; 74: 694–695.
27. Taylor J, Ansell I. Sarcoid sensitive nephritic syndrome and renal impairment in a patient with sarcoidosis. *Nephrol Dial Transplant* 1996; 11: 355–356.
28. Nishiki M, Murakama Y, Yamane Y, *et al.* Steroid sensitive nephritic syndrome, sarcoidosis and thyroiditis. *Nephrol Dial Transplant* 1999; 14: 2008–2010.

29. Schmidt R, Bender F, Change W, *et al.* Sarcoidosis after renal transplant. *Transplantation* 1999; 68: 1420–1423.
30. Hamada H, Nagai S, Ono T, *et al.* Sarcoidosis complicated with IgA nephropathy. *Sarcoidosis Vasc Diffuse Lung Dis* 2003; 20: 69–73.
31. Gobel V, Kettritz R, Schneider W, *et al.* The protean face of renal sarcoidosis. *J Am Soc Nephrol* 2001; 12: 616–623.
32. Marinides G, Hajdu I, Grans R. Unique association of renal carcinoma and sarcoid reaction in the kidney. *Nephron* 1994; 67: 477–480.
33. Moder K, Litin S, Gaffey T. Renal cell carcinoma associated with sarcoid-like tissue reaction. *Mayo Clin Proc* 1990; 65: 1498–1501.
34. Campbell F, Douglas-Jones A. Sarcoid-like granulomas in primary renal-cell carcinoma. *Sarcoidosis* 1993; 10: 128–131.
35. Hoffbrand B. The kidney in sarcoidosis. In: James DG, ed. *Sarcoidosis and other Granulomatous Disorders*. New York, NY, Marcel Dekker, 1994; pp. 335–343.
36. Bell N, Stern P, Pantzer E, *et al.* Evidence that increased circulating 1 alpha, 25-dihydroxy vitamin D is the probable cause for abnormal calcium metabolism in sarcoidosis. *J Clin Invest* 1979; 64: 218–225.
37. Mitchell T, Stamp T, Jenkins J. Hypercalcemic sarcoidosis in hypoparathyroidism. *BMJ* 1983; 1: 764–765.
38. Zimmerman J, Holick M, Silver J. Normocalcemia in hypothyroid patient with sarcoidosis: evidence for parathyroid hormone independent synthesis of 1,25-dihydroxy vitamin-D. *Ann Intern Med* 1983; 98: 338–340.
39. Barbour G, Coburn J, Slatopolsky E, Norman AW, Horst RL. Hypercalcemia in an anephric patient with sarcoidosis: evidence for extrarenal generation of 1,25-dihydroxyvitamin D. *N Engl J Med* 1981; 305: 440–443.
40. Henneman P, Dempsey E, Carol E, *et al.* The causes of hypercalcemia in sarcoidosis and its treatment with cortisone and sodium phytate. *J Clin Invest* 1956; 35: 1229–1242.
41. Adams JS, Sharma OP, Gacad MA, Singer FR. Metabolism of 25-hydroxyvitamin D3 by cultured pulmonary alveolar macrophages in sarcoidosis. *J Clin Invest* 1983; 72: 1856–1860.
42. Mason R, Frankel T, Chan Y, *et al.* Vitamin D conversion by sarcoid lymph node homogenate. *Ann Intern Med* 1984; 100: 59–61.
43. Seldes G. *The Great Quotations*. Secaucus, NJ, Castle Books, 1960; p. 226.
44. Cadranel J. Vitamin D, endocrine and paracrine mediators in cases of pulmonary granulomatosis. *Rev Mal Respir* 1995; 12: 119–120.
45. Bhalla A, Amento E, Clemens T, *et al.* Specific high-affinity receptors for 1,25-dihydroxy vitamin D3 in human peripheral blood mononuclear cells, presence in monocytes and induction in T lymphocytes following activation. *J Clin Endocrinol Metab* 1983; 57: 1308–1310.
46. Rigby W, Noelle R, Krause K, *et al.* The effect of 1, 25-dihydroxy vitamin D on human T lymphocyte activation and proliferation: a cell cycle analysis. *J Immunol* 1985; 135: 2279–2286.
47. Haq A. 1-25-Dihydroxy vitamin D (calcitriol) suppresses IL-2 murine thymocyte proliferation. *Thymus* 1986; 8: 295–306.
48. Adams J, Modlin R, Diz MM, Barnes PF. Potentiation of the macrophage 25-hydroxyvitamin D-1-hydroxylation reaction by human tuberculous pleural effusion fluid. *J Clin Endocrinol Metab* 1989; 69: 457–460.
49. Barnes P, Modlin R, Bikle D, *et al.* Transpleural gradient of 1,25-dihydroxy vitamin D in tuberculous pleuritis. *J Clin Invest* 1989; 83: 1527–1532.
50. Provvedini D, Tsoukas C, Deftos L, *et al.* 1 α ,25-Dihydroxyvitamin D-binding macromolecules in human B-lymphocytes: effects on immunoglobulin production. *J Immunol* 1986; 136: 2734–2740.
51. McFadden R, Vickers K, Fraher L. Lymphocyte chemokinetic factors derived from human tonsils: modulation by 1,25-dihydroxy vitamin D (calcitriol). *Am J Respir Cell Mol Biol* 1991; 4: 42–49.
52. Rigby W, Denome S, Fanger M. Regulation of lymphokine production and human T lymphocyte activation by 1,25-dihydroxy vitamin D3. *J Clin Invest* 1987; 79: 1659–1664.

53. Sharma O. Hypercalcemia in granulomatous disorders: a clinical review. *Curr Opin Pulm Med* 2000; 6: 442–447.
54. McCort J, Wood R, Hamilton J, *et al.* Sarcoidosis: a clinical and roentgenographic study of 28 proven cases. *Arch Intern Med* 1947; 80: 293–321.
55. Cummings M. Epidemiologic and clinical observations in sarcoidosis. *Ann Intern Med* 1959; 50: 879–890.
56. Mayock R, Bertrand P, Morrison C, *et al.* Manifestations of sarcoidosis: an analysis of 145 patients with a review of nine series from the literature. *Am J Med* 1963; 35: 67–89.
57. Scadding J. The kidney and calcium metabolism in sarcoidosis. In: Scadding JG, Mitchell DN, eds. *Sarcoidosis*. London, Chapman and Hall Medical, 1985: pp. 390–413.
58. Mather G. Calcium metabolism and bone changes in sarcoidosis. *BMJ* 1957; 1: 248–253.
59. Putkonen T, Hannuksela N, Hahme H. Calcium and phosphorus metabolism in sarcoidosis. *Acta Med Scand* 1965; 177: 327–335.
60. James D, Neville E, Siltzbach L. A worldwide review of sarcoidosis. *Ann N Y Acad Sci* 1976; 278: 321–334.
61. Cronin C, Dimnear S, O'Mahony D, *et al.* Precipitation of hypercalcemia in sarcoidosis by foreign sun holidays: report of four cases. *Postgrad Med J* 1990; 307–309.
62. Webb AR, Kline L, Holick MF. Influence of season and latitude on the cutaneous synthesis of vitamin D₃: exposure to winter sunlight in Boston and Edmonton will not promote vitamin D₃ synthesis in human skin. *J Clin Endocrinol Metab* 1988; 67: 373–378.
63. Harrell G, Fisher S. Blood chemical changes in Boeck's sarcoid with particular reference to protein, calcium and phosphorus values. *J Clin Invest* 1939; 18: 687–693.
64. Taylor R, Lynch H, Winsor W. Seasonal influence of sunlight on the hypercalcemia of sarcoidosis. *Am J Med* 1963; 35: 67–69.
65. Dent C. Calcium metabolism in sarcoidosis. *Postgrad Med J* 1970; 46: 471–473.
66. Hendrix J. The remission of hypercalcemia and hypercalciuria in systemic sarcoidosis by vitamin D depletion. *Clin Res* 1963; 11: 220–225.
67. Sharma O, Trowell J, Cohen N, *et al.* Abnormal calcium metabolism in sarcoidosis. In: Turiaf J, Chabot J, eds. *La Sarcidose: Rapports de la IV Conference Internationale*. [Proceedings of the IV International Conference on Sarcoidosis]. Paris, Masson & Cie, 1967; pp. 627–631.
68. Mundy G, Raisz L, Cooper R, *et al.* Evidence for the secretion of an osteoclast stimulating factor in myeloma. *N Engl J Med* 1974; 291: 1041–1046.
69. Broulik P, Votava V, Pacovsky V. The tubular maximum for calcium reabsorption in patients with chronic active sarcoidosis. *Eur Respir J* 1990; 3: 447–449.
70. Adams J, Diz M, Sharma O. Effective reduction in the serum 1,25-dihydroxy vitamin D and calcium concentration in sarcoidosis associated hypercalcemia with short course of chloroquine therapy. *Ann Intern Med* 1989; 111: 437–438.
71. Barre P, Gascon-Barre M, Meakins J, *et al.* Hydroxychloroquine treatment of hypercalcemia in a patients with sarcoidosis undergoing hemodialysis. *Am J Med* 1987; 82: 1259–1262.
72. O'Leary T, Jones G, Yip A, *et al.* The effects of chloroquine on serum 1,25-dihydroxy vitamin D and calcium metabolism in sarcoidosis. *N Engl J Med* 1986; 315: 727–730.
73. Adams JS, Sharma OP, Diz MM, Endres DB. Ketoconazole decreases the serum 1,25-dihydroxy vitamin D and calcium concentration in sarcoidosis-associated hypercalcemia. *J Clin Endocrinol Metab* 1990; 70: 1090–1095.
74. Ejaz AA, Zabaneh RI, Tiwari P, Nawab ZM, Leehey DJ, Ing TS. Ketoconazole in the treatment of recurrent nephrolithiasis associated with sarcoidosis. *Nephrol Dial Transplant* 1994; 9: 1492–1494.
75. Sharma OP, Alfaro C. Hypercalciuria and renal stones in a sarcoidosis patient treated by extracorporeal shockwave lithotripsy. *Sarcoidosis* 1986; 3: 7–9.