

# **Neurosarcoidosis**

E. Hoitsma<sup>\*,#</sup>, O.P. Sharma<sup>\*</sup>

<sup>\*</sup>Dept of Neurology and <sup>#</sup>Sarcoidosis Management Centre, University Hospital Maastricht, Maastricht, The Netherlands, and <sup>\*</sup>Dept of Pulmonary and Critical Care Medicine, Keck School of Medicine, University of Southern California, Los Angeles, CA, USA.

Correspondence: O.P. Sharma, Room 11-900, LAC+USC Medical Center, 1200 North State Street, Los Angeles, CA 90033, USA. Fax: 1 3232262728; E-mail: osharma@usc.edu

Sarcoidosis is an inflammatory multisystemic disorder. Its cause is not known. The disease may involve any part of the nervous system. The incidence of clinical involvement of the nervous system in a sarcoidosis population is estimated to be ~5–15% [1, 2]. However, the incidence of subclinical neurosarcoidosis may be much higher [3, 4]. Necropsy studies suggest that *ante mortem* diagnosis is made in only 50% of patients with nervous system involvement [5]. As neurosarcoidosis may manifest itself in many different ways, diagnosis may be complicated [2, 3, 6–10]. It may appear in an acute explosive fashion or as a slow chronic illness. Furthermore, any part of the nervous system can be attacked by sarcoidosis, but the cranial nerves, hypothalamus and pituitary gland are more commonly involved [1]. Sarcoid granulomas can affect the meninges, parenchyma of the brain, hypothalamus, brainstem, subependymal layer of the ventricular system, choroid plexuses and peripheral nerves, and also the blood vessels supplying the nervous structures [11, 12]. One-third of neurosarcoidosis patients show multiple neurological lesions. If neurological syndromes develop in a patient with biopsy-proven active systemic sarcoidosis, the diagnosis is usually easy. However, without biopsy evidence of sarcoidosis at other sites, nervous system sarcoidosis remains a difficult diagnosis [13]. Neurological symptoms may also arise in patients with inactive sarcoidosis. In such situations, neurosarcoidosis may occupy a high place in the list of differential diagnoses, but histological evidence of granulomatous involvement of the neurological apparatus is still required in these cases. Furthermore, in a smaller number of patients, sarcoidosis may selectively involve the nervous system [14, 15]. In such cases, it is important not to confuse the nonspecific local sarcoid reaction with multisystemic sarcoidosis [16]. Neurosarcoidosis is rare; most articles report small numbers of patients or case reports, and prospective studies on neurosarcoidosis are scarce [17]. Consequently, evidence-based recommendations are lacking.

## **Neurological manifestations of sarcoidosis**

### ***Cranial neuropathy***

Cranial neuropathy is the most frequent neurological complication of sarcoidosis (table 1) [1]. Cranial nerve palsy may be due to nerve granulomas, increased intracranial pressure or granulomatous basal meningitis. A peripheral seventh nerve palsy (Bell's palsy) is the single most common cranial nerve lesion [1], and is, indeed, the most

**Table 1. – Manifestation of cranial neuropathies in neurosarcoidosis**

Cranial nerve	Manifestation
I: olfactory [18, 19]	Anosmia <sup>#</sup>
II: optic [20, 21]	Diminished visual acuity, papilloedema
III: oculomotor [22]	Ophtalmoplegia, diplopia, ptosis
IV: trochlear [22]	Ophtalmoplegia, diplopia
V: trigeminal [23]	Hypoaesthesia, neuralgia
VI: abducent [22]	Ophtalmoplegia, diplopia
VII: facial [24, 25]	Bell's palsy
VIII: vestibulocochlear [18, 26, 27]	Vertigo, hearing loss
IX: glossopharyngeal [22]	Dysarthria, dysphagia
X: vagus [28–30]	Dysarthria, dysphagia, postural symptoms
XI: accessory [22]	Sternocleidomastoid weakness, trapezius weakness
XII: hypoglossal [22]	Dysarthria, dysphagia

<sup>#</sup>: may be due to sarcoidosis of the nasal mucosa.

frequent neurological manifestation of sarcoidosis overall [2, 3, 9, 18, 22, 31]. Bilateral dysfunction occurs, both simultaneously and sequentially.

The optic nerve is the second most commonly affected cranial nerve [31]. Although sarcoid granulomas of the optic nerve are usually unilateral, they may involve both nerves [32]. Sarcoidosis of the optic nerve may occur without systemic involvement [33]. When optic neuropathy occurs, especially in young patients, multiple sclerosis is considered a likely cause. In these cases a chest radiograph with evidence of sarcoidosis makes multiple sclerosis highly unlikely [34]. Optic nerve involvement due to sarcoidosis can be divided into a chronic progressive type that responds poorly to corticosteroids [35] and an acute type that responds to prednisone [2, 35, 36].

Other cranial nerves may also be affected. Cranial neuropathies may be single or multiple [37, 38]. Heerfordt's syndrome consists of cranial neuropathy (mostly the facial nerve), uveitis, parotid gland enlargement and fever. This syndrome is highly suggestive of sarcoidosis.

Finally, Horner's syndrome due to disruption of the cervical sympathetic nerves [1], as well as pupillary abnormalities, including internal ophthalmoplegia, Argyll Robertson pupil and Adie's pupil, have been described in sarcoidosis [18, 39–42].

### ***Papilloedema***

The diagnosis of neurosarcoidosis should be entertained in young adults, particularly females of childbearing age, with rapidly developing papilloedema, especially associated with the seventh or other nerve palsies. In sarcoidosis patients, fundoscopy should always be performed.

### ***Aseptic meningitis***

Meningeal symptoms may be acute or chronic. Symptoms and signs include fever, headache, neck rigidity and sterile cerebrospinal fluid (CSF) with pleocytosis (particularly lymphocytes) [43]. CSF glucose levels may be low in approximately one-fifth of patients [44]. Sometimes mental status changes and polyradiculopathy are present [45, 46]. The basal meninges may be affected, resulting in cranial neuropathy. Chronic meningitis is often recurrent and requires long-term therapy, whereas acute meningitis responds favourably to corticosteroids.

## ***Hydrocephalus***

Hydrocephalus is rare and may occur due to impaired absorption [12, 14, 47] or obstruction [48, 49]. Besides causing headache and somnolence, hydrocephalus may produce amnesia, dementia, urinary incontinence and gait disturbances [50, 51].

## ***Cerebral sarcoid lesions***

Granulomas may remain small or form large intracranial tumours and may be single or multiple. They can occupy extradural, subdural and parenchymatous locations [52–55]. Occasionally, periventricular white matter lesions are observed (fig. 1a). The latter may resemble multiple sclerosis or vascular changes. Asymptomatic periventricular white matter lesions without meningeal enhancement in sarcoidosis patients aged >50 yrs are most probably not due to sarcoidosis and can be regarded as age-related small vessel disease.

The clinical features of mass lesions are similar to those of any space-occupying intracranial mass. Granulomatous lesions are relatively frequently found in the hypothalamus and/or pituitary gland [56–60]. This may cause endocrine manifestations, such as diabetes insipidus [61], adenopituitary failure [62, 63] and amenorrhoea–galactorrhoea syndrome [59], isolated or in various combinations. Infratentorial granulomas are less common than supratentorial but cerebellar masses also occur [22]. When no evidence of systemic sarcoidosis is found, differential diagnosis of pituitary lesions consists of pituitary adenoma and lymphocytic adenohypophysitis [64].

Granulomatous cerebral angiitis also occurs in sarcoidosis [14, 65]. Ophthalmological screening is helpful in uncovering angiitis. Diffuse cerebral vasculopathy may produce psychosis, dementia and epileptic seizures [47, 66–70]. Pseudotumour cerebri due to dural

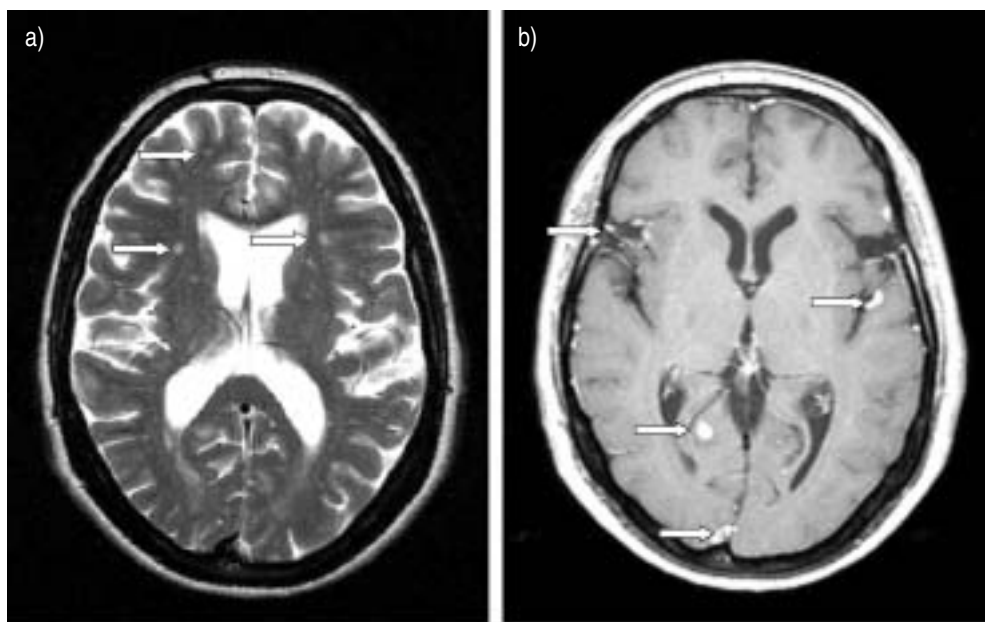


Fig. 1. – Cerebral magnetic resonance imaging of case A: a) T1-weighted, revealing nonspecific white matter lesions (arrows); and b) gadolinium-enhanced T2-weighted, revealing leptomeningeal-enhancing lesions (arrows).

sinus thrombosis as a presenting manifestation of neurosarcoidosis has also been reported [71, 72].

**Case A.** A 55-yr-old female was seen for a second opinion. She had suffered from low back pain, leg weakness and atypical position-independent dizziness and headache for 10 months. Physical examination revealed bilateral pyramidal syndrome with UK Medical Research Council (MRC) grade 4/5 paraparesis of both iliopsoas, hamstring and quadriceps muscles. She had extensor plantar responses and a pyramidal gait. Cerebral magnetic resonance imaging (MRI) revealed nonspecific, nonenhancing white matter lesions and leptomeningeal enhancing lesions (fig. 1). Spinal MRI showed a hyperintense enhancing lesion at the 5th–6th cervical spinal level. Lumbar puncture revealed a cell density of  $19 \text{ white blood cells} \cdot \text{mm}^{-3}$  (100% lymphocytes) without signs of malignancy and increased protein and normal glucose and angiotensin-converting enzyme (ACE) levels. Her history revealed pneumonia 4 months previously, just before the neurological symptoms had started, and a tongue lesion for almost a year, which had been diagnosed as a benign mycosis. On presentation, her tongue lesion was causing her more and more trouble. Chest computed tomography (CT) revealed hilar adenopathy and pulmonary infiltrates, and biopsy of the tongue lesion showed noncaseating granulomas, both consistent with a diagnosis of sarcoidosis. She was treated with prednisone, after which her symptoms improved. At present, she is still continuing her medication.

### *Seizures*

Seizure may be the first manifestation of neurosarcoidosis; any type of seizure may occur. The presence of seizures indicates chronicity and poor prognosis [73].

**Case B.** A 19-yr-old female presented in the emergency department with a first tonic-clonic generalised seizure and postictal headache, confusion and dysphasia. Contrast-enhanced CT and MRI revealed a left parieto-occipital enhancing lesion (fig. 2). Differential diagnosis included malignancy, and lumbar puncture was performed, which showed lymphocytosis without signs of malignancy. Laboratory investigation, including calcium, ACE and lysozyme levels and erythrocyte sedimentation rate (ESR), revealed no abnormalities. Chest radiography was performed in search of primary malignancy, which showed hilar adenopathy and a pulmonary infiltrate. Mediastinal lymph node biopsy showed noncaseating granulomas consistent with the diagnosis of sarcoidosis. She was treated with prednisone and valproate and remained well for a period of 1 yr without abnormalities on control CT. When prednisone was tapered down, she had two recurrences, with cranial neuropathy and multiple cerebral enhancing lesions, and is finally stable on 15 mg prednisone.

### *Psychiatric symptoms*

Granulomatous infiltration of the central nervous system (CNS) may produce a wide variety of mental symptoms. In a patient with multisystemic sarcoidosis and unexplained mental deterioration, aggressive evaluation of the CNS is indicated. Symptoms may respond to corticoid therapy [47, 69]. A subset of sarcoidosis patients present with mild amnesic problems, without objective deterioration or neurological deficit. This might be related to fatigue and concentration problems, or, in some cases, to postural tachycardia syndrome (autonomic dysfunction; see case E) [74]. However, further study using neuropsychological testing is required to explore this.

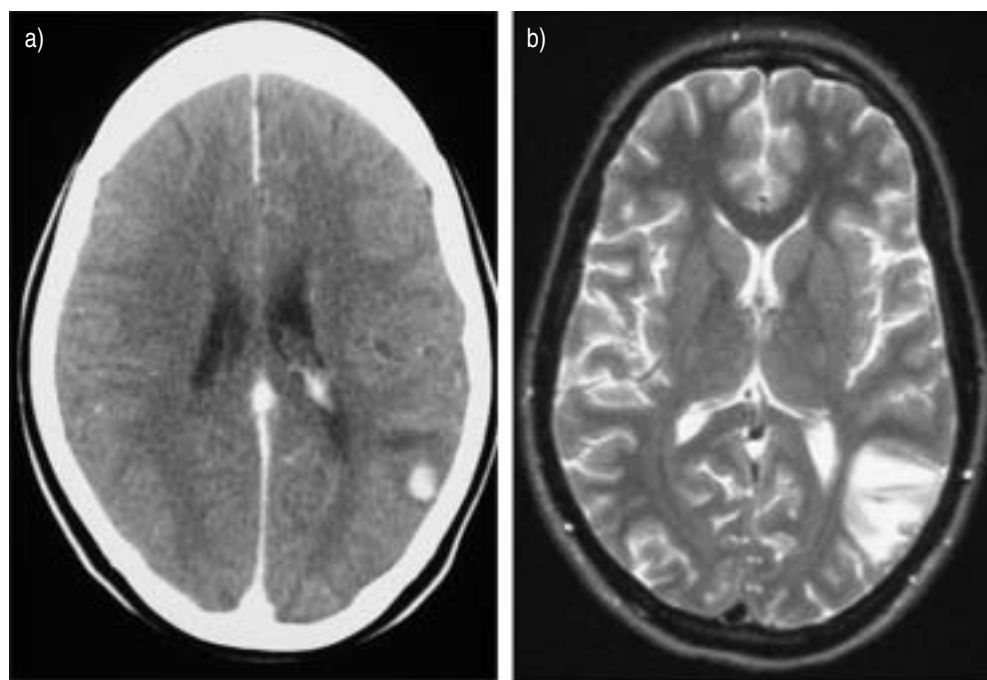


Fig. 2. – Post-contrast images showing a left parieto-occipital enhancing lesion in case B: a) computed tomography; and b) T2-weighted magnetic resonance imaging.

### ***Spinal sarcoidosis***

Spinal sarcoidosis encompasses a spectrum of intraspinal diseases, including arachnoiditis, extradural and intradural extramedullary lesions, and intramedullary lesions [1, 75, 76]. Intramedullary spinal involvement is one of the rare manifestations of the disease (fig. 3). Granulomas involving the spinal cord are often clinically and radiologically indistinguishable from a malignant tumour [77, 78]. Patients may present with transverse myelopathy with para- or tetraparesis [75, 79–81], autonomic dysreflexia [82] radicular syndrome [75] and cauda equina syndrome [83–88].

**Case C.** A 33-yr-old Iranian male with paresis of the left leg who had had muscle cramps for 2 months and urine retention for 2 weeks presented for a second opinion. His medical history included histologically proven pulmonary sarcoidosis with spontaneous recovery of pulmonary symptoms 6 months before presentation. Physical examination revealed diffuse MRC grade 4/5 paresis of the left leg, clonus of the knee and ankle tendon reflex on the left side and bilateral extensor plantar responses. There was decreased pain, vibration and light touch sensation in both legs until the first thoracic spinal level. The results of laboratory investigation, including ESR and levels of ACE and CSF ACE, protein, glucose and white blood cells, were all within normal limits. Cerebral MRI revealed no abnormalities, whereas spinal MRI showed a medullar lesion at the 2nd–5th cervical level (fig. 3). Subsequently, chest radiography was performed because of the patient's medical history, and, again, hilar adenopathy was found, compatible with a diagnosis of sarcoidosis. Treatment with 80 mg prednisone *q.d.* was started, preceded by a *q.d.* dose of 1,000 mg methylprednisolone intravenously for 3 days. The neurological situation

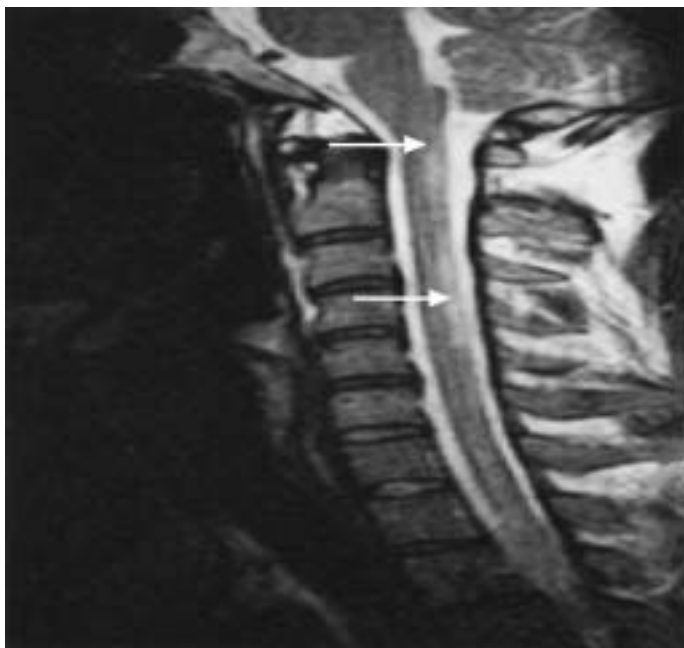

Fig. 3. – T2-weighted magnetic resonance imaging of the cervical spine in case C, showing hyperintense lesions at the 2nd–5th cervical spinal level (arrows)

stabilised. However, when prednisone was tapered after 10 weeks, symptoms increased. Methotrexate was then started. At present, the patient is stable on 10 mg methotrexate once a week along with 10 mg prednisone and 1 mg folic acid (*q.d.*).

### ***Peripheral neuropathy***

The clinical and pathological spectrum of sarcoid neuropathy is wide. Peripheral neuropathy is considered to be rare in sarcoidosis [89, 90]. The pattern of large-fibre neuropathy reported in sarcoidosis includes multiple mononeuropathies, polyradiculopathy, Guillain-Barré syndrome and symmetric distal polyneuropathy, which may be sensorimotor, mostly sensory or mostly motor [14, 90–102]. Epineural and perineural granulomas and granulomatous vasculitis can cause ischaemic axonal degeneration and demyelination due to local pressure [89, 93, 94]. Nerve biopsy may be helpful in diagnosing problems. In most patients, the clinical course of sarcoid neuropathy is subacute [93], and many patients seem to respond to corticosteroid therapy [17].

### ***Small fibre neuropathy***

Recently small fibre neuropathy (SFN) was demonstrated in sarcoidosis [103–105] and appeared to be relatively frequent [104]. However, as standard nerve conduction tests evaluate only large nerve fibre function and quantitative techniques for the assessment of small nerve fibres are not routinely applied, the diagnosis of SFN can easily be missed. SFN has only relatively recently been recognised as a distinct entity. If not recognised, these symptoms may be an enigma to both patient and doctor. Recognition of SFN is important as it may cause disabling symptoms. SFN may also involve autonomic nerve

fibres and, apparently, cardiac sympathetic denervation [106]. Whether life-threatening symptoms, such as cardiac arrhythmias, occur in sarcoidosis when cardiac autonomic denervation is involved requires further study. SFN may also cause restless leg syndrome (RLS) [107]. RLS and periodic limb movement disorder (PLMD) are frequently associated and related to sleep disturbances. PLMD and RLS have been found to be present in sarcoidosis [108]. In table 2, symptoms suggestive of SFN are presented. The pathophysiology and treatment of SFN in sarcoidosis are unknown and need further study.

**Case D.** A 55-yr-old male with known pulmonary sarcoidosis for 2 yrs was referred to the neurology department because of severe pain in his hands and lower legs and feet with paraesthesiae. He could not tolerate bedclothes on his legs, and wore short trousers without socks in winter because he could not tolerate clothes on his lower legs. Furthermore, he was suffering from severe fatigue, profuse sweating, diarrhoea, bladder emptying difficulties, sicca syndrome, paroxysmal palpitations with dizziness, after which he once collapsed, and erectile dysfunction. Neurological examination revealed no abnormalities except subjective dysaesthesia of the lower legs and feet. Differential diagnosis included neuropathy with involvement of autonomic fibres. Electromyography (EMG), nerve conduction studies and cardiovascular autonomic function test results were normal. Thermal threshold testing (TTT) revealed abnormal temperature sensation compatible with SFN. He was treated with prednisone without any success, and subsequently put on methotrexate, again without any improvement. Neuropathic pain treatment [109–112] with gabapentin, amitriptyline, carbamazepine and local capsaicin cream were all without benefit. Opioids gave some pain reduction and improved diarrhoea. However, after a few weeks, he developed urine retention. At present, the patient is severely disabled, mainly because of severe pain and fatigue, and has had to stop working.

**Case E.** A 39-yr-old male with known pulmonary and neurological involvement (hydrocephalus) of sarcoidosis since 2000 presented at the neurology department for a second opinion in 2003 with symptoms of extreme fatigue, cognitive impairment, pain in the palms and soles, weakness of the legs, and dizziness and blurred vision while standing. He had been suffering from these symptoms for 2 yrs. Cerebral MRI revealed unchanged hydrocephalus without any parenchymal lesions, and lumbar puncture showed normal pressure and normal cell counts and protein and glucose levels. The posture-dependent symptoms in combination with pain in the palms and soles were suggestive of SFN.

**Table 2. – Symptoms suggestive of small fibre neuropathy**

Sensory symptoms
Pain
Paraesthesiae
Sheet intolerance
Restless leg syndrome
Symptoms of autonomic dysfunction
Hypo- or hyperhidrosis
Diarrhoea or constipation
Urinary incontinence or retention
Gastroparesis
Sicca syndrome
Blurry vision
Facial flushes
Orthostatic intolerance
Sexual dysfunction

Therefore, TTT was performed, revealing severely abnormal temperature sensation. Cardiovascular autonomic function testing showed autonomic dysfunction. There was a normal blood pressure response after changing position from the supine to standing position, but an abnormal increase in cardiac frequency (to 63 beats·min<sup>-1</sup>; normally <30 beats·min<sup>-1</sup>). Furthermore, blood pressure modulation frequency in the upright position was too low (0.051 Hz). Both results, as well as the symptoms, are consistent with the diagnosis of postural tachycardia syndrome [74]. He was treated with hydration, increased salt intake and elastic support hose without much benefit. At present, he is on 50 µg fludrocortisone *q.d.*, with some improvement in his symptoms.

### ***Skeletal muscle involvement***

Muscle involvement may be symptomatic or asymptomatic [113, 114]. Asymptomatic granulomatous muscle involvement in sarcoidosis has been reported with a prevalence of 50–80% [115], whereas symptomatic muscle involvement is much less common (range 1.4–2.3%) [116]. Patients usually present with pain, weakness and tenderness of the involved muscles, muscle atrophy and sometimes even muscle cramps and contractures [116]. Symptomatic involvement may be divided into the following types: 1) a palpable nodular type, which is seen less frequently; 2) an acute myositis, which is rare and seen more commonly in females; and 3) a chronic myopathic type, which is more common, is slower in onset and occurs later in life [114, 116–118]. As, in the majority, the granulomatous infiltration is in connective tissue structures and necrosis of muscle fibres is uncommon, EMG results may be quite normal [113]. However, EMG can reveal myopathic changes. It may be difficult to distinguish myopathy due to sarcoidosis itself from myopathy due to steroids, especially in chronic myopathy. In the first case, steroids are indicated, whereas, in the second, steroids should be tapered. Steroid myopathy is mostly seen with fluorinated corticosteroids (dexamethasone, triamcinolone and betamethasone). A helpful distinction between the two is presented in table 3. Muscle biopsy is most helpful here. Essentially, in sarcoid myopathy, lesions take the form of granulomata in connective tissue, particularly in a perivascular distribution. The lesions are quite focal and serial sections increase the chances of establishing a diagnosis [114]. In steroid myopathy, type 2 fibre atrophy is typically found.

## **Diagnosis**

Virtually every neurological problem could, indeed, be due to neurosarcoidosis, but only few combinations of symptoms are clinically suggestive of neurosarcoidosis (table 4). The diagnosis of neurosarcoidosis requires a compatible clinical or radiological

**Table 3. – Differences between myopathy due to sarcoidosis and due to steroids**

	Steroid-induced myopathy	Sarcoid myopathy
Clinical features	Myalgia; proximal weakness, especially legs	Myalgia; weakness: proximal>distal; sometimes palpable nodules, contractures or cramp
Creatine kinase	Mostly normal	Sometimes elevated
Frequency	Low: 2–21% in all patients receiving steroids	50% of sarcoidosis patients have muscle granulomas, often asymptomatic
Electromyography	Low amplitude MUPs of short duration	Fibrillations and positive sharp waves; low amplitude MUPs of short duration
Biopsy	Type-2 fibre atrophy	Myositis; nodular myositis

MUP: motor unit potential.



**Table 4. – Neurosarcoidosis: differential diagnosis**

	Neurosarcoidosis	Multiple sclerosis	Behçet's disease	Infections
Age yrs	20–40	20–40	20–40	Any
Sex	Equal	F>M	M>F	Equal
Chest radiograph	Abnormal >90%	Usually normal	May be abnormal	May be abnormal
Hypercalcaemia	Present <15%	Absent	Absent	May be present
Uveitis	Present 25%	Absent	May be present	May be present
Facial nerve involvement	May occur	May occur	Absent	Absent
Meningitis	May occur	May occur	May occur	May occur
CSF ACE	Present	Absent	Absent	Absent
CSF lysozyme	Present	Absent	Absent	Present
Oligoclonal IgG	Present 30%	Present 90%	Absent	May be present
Kveim test	Positive	Negative	Negative	Negative

CSF: cerebrospinal fluid; ACE: angiotensin-converting enzyme; Ig: Immunoglobulin; F: female; M: male.

picture of sarcoidosis and histological confirmation of noncaseating granulomas [119, 120]. Three clinical situations can be distinguished in patients with neurosarcoidosis: 1) patients with neurological features and histologically confirmed active systemic sarcoidosis; 2) patients with neurological features and a history of sarcoidosis without any evidence of activity; and 3) patients with neurological features without a history of or any evidence of systemic sarcoidosis.

In the first situation, neurological symptoms are most probably related to systemic sarcoidosis and there is justification in starting therapy (fig. 4). However, when treatment fails, the diagnosis should be reassessed and an attempt made to obtain biopsy specimens in order to establish the correct diagnosis. In the second situation, in patients with a history of sarcoidosis who present with neurological symptoms, neurosarcoidosis will be considered early in the differential diagnosis. The need for biopsy is crucial in such a situation. Conversely, in the third situation, neurosarcoidosis will rarely be considered at an early stage. In these cases, neurosarcoidosis remains one of the more challenging diagnostic problems [121, 122]. The present authors believe that the diagnostic approach in the second and third situations should be the same (fig. 5). A prior history of

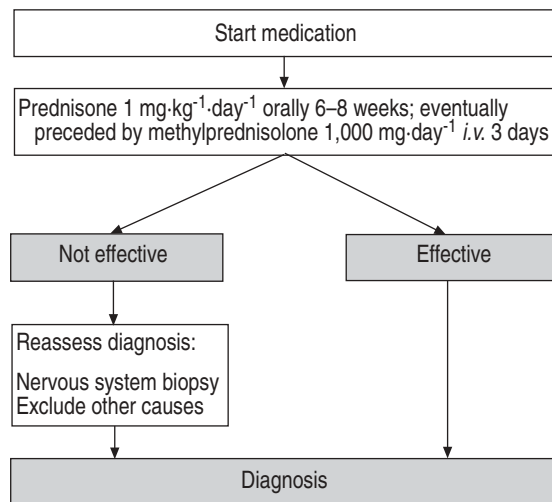


Fig. 4. – Diagnostic flow chart for patients with active systemic sarcoidosis and presentation with neurological symptoms.

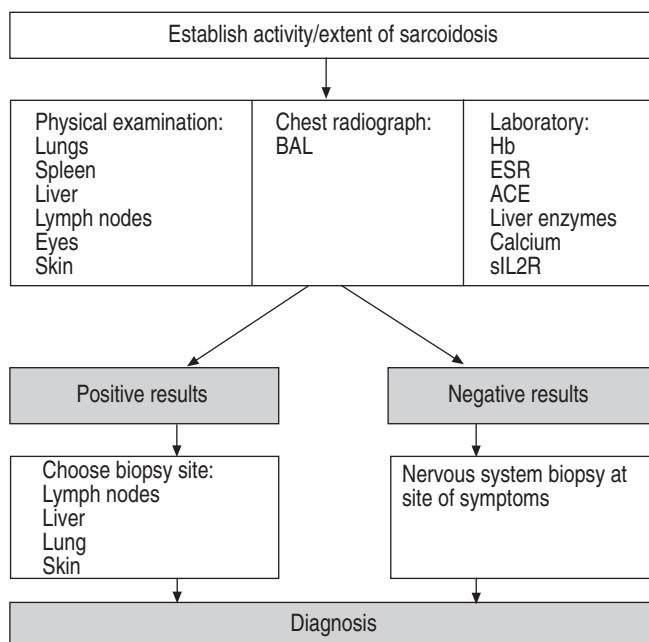


Fig. 5. – Diagnostic flow chart for patients not known to have sarcoidosis with neurological symptoms and for patients with a history of sarcoidosis but without signs of active disease. BAL: bronchoalveolar lavage; Hb: haemoglobin; ESR: erythrocyte sedimentation rate; ACE: angiotensin-converting enzyme; sIL-2R: soluble interleukin-2 receptor.

sarcoidosis does not necessarily mean that any new problem of the patient is automatically attributable to sarcoidosis. In the authors' opinion, the approach in a patient with a prior history of sarcoidosis without evidence of current active disease should be the same as in a patient without a history of sarcoidosis.

In figures 4 and 5, the possible steps in establishing a diagnosis are presented [109, 120]. Whole-body gallium scanning [123, 124] or fluorodeoxyglucose positron emission tomography (PET) [125] can be utilised in finding other suitable sites for biopsy. Conjunctival biopsy, a technically simple, inexpensive and safe method, may also be used for diagnosis. Given that as many as 54.1% of patients with sarcoidosis exhibit ocular abnormality, it is worthwhile referring suspected cases for ophthalmological assessment and considering conjunctival biopsy as a method of tissue diagnosis [126–128].

While excluding other causes, the differential diagnosis of sarcoidosis should be taken into account (table 5). Finally, if no evidence of systemic sarcoidosis is found but a CNS biopsy reveals a sarcoid-like granulomatous reaction, there should be awareness of the distinction between systemic neurosarcoidosis and a local (neurological) sarcoid-like reaction, particularly related to an old scar [129] or a helminthic reaction [16, 109, 130].

### Neuroimaging

Neuroimaging studies, and especially MRI, are the most sensitive diagnostic tools in detecting and localising neurological lesions. These tests, however, are not specific, since radiological expressions are highly variable [131, 132].

**Table 5. – differential diagnosis of neurosarcoidosis**


---

Infectious diseases
Leprosy
Tuberculosis
Whipple's disease
Toxoplasmosis
Mycosis
Helminthic infections
Treponemal infections
Lyme disease
Granulomatous diseases
Wegener's granulomatosis
Churg–Strauss syndrome
Lymphomatoid granulomatosis
Tumours
Neurolymphomas
Gliomas
Meningiomas
(Leptomeningeal) metastases
Vasculopathies
Vasculitis
Behçet's disease
Systemic diseases
Amyloidosis
Chronic subdural haematoma
Neurological diseases
Multiple sclerosis
Acute demyelinating encephalomyelitis

---

### ***Cerebrospinal fluid***

Routine CSF abnormalities are usually nonspecific and include mild pleocytosis, increased protein content and sometimes mildly decreased glucose levels. Furthermore, elevations of ACE [133–139], immunoglobulin G index [140–142], oligoclonal bands [9, 140, 141], CD4:CD8 lymphocyte ratios [143], and lysosyme and  $\beta_2$ -microglobulin levels [144] have been reported in CSF. Approximately one-third of patients with neurosarcoidosis show normal CSF [11, 18, 119]. Moreover, in conditions such as multiple sclerosis and systemic lupus erythematosus, similar CSF abnormalities may be found.

CSF ACE levels appear to be elevated in more than half of patients with neurosarcoidosis [134]. It should be emphasised, however, that high levels of CSF ACE are not specific to neurosarcoidosis and have also been reported in CNS infections and malignant tumours [134, 139]. Several studies found significantly higher CSF ACE levels in active neurosarcoidosis compared to controls and compared to sarcoidosis without nervous system involvement [133–139]. Furthermore, in serial measurements of CSF ACE, reflection of the clinical picture was found [137, 138, 145]. No correlation was found between serum and CSF ACE levels in patients with neurosarcoidosis, nor was there any correlation between serum ACE levels and the clinical picture or CSF ACE and CSF total protein or CSF albumin levels in such patients (an increase in CSF albumin level being an indicator of functioning of the blood-brain barrier). Thus, CSF ACE is most probably synthesised in the nervous system and released into the CSF by the CNS system sarcoid granulomas. In conclusion, determination of CSF ACE level is not specific for neurosarcoidosis, but seems to be particularly useful in monitoring disease activity and treatment response.

---

### ***Neurophysiological studies***

Electroencephalography may reflect an early stage of acute encephalomeningitis and epileptic discharges caused by the neurosarcoidosis. Visual evoked potentials, brainstem evoked potentials and trigeminofacial reflexes can be useful in detecting cranial neuropathy.

EMG and nerve conduction studies reveal large fibre neuropathy and myopathy, whereas TTT and/or skin biopsy are needed to assess SFN. The latter techniques are not yet routinely available. Assessment of autonomic dysfunction, present in SFN, requires special equipment, such as quantitative sudomotor axon reflex testing. Cardiovascular autonomic function testing using the so-called Ewing tests has a low sensitivity for autonomic dysfunction in SFN [104, 146]. The widely available testing of sympathetic skin response is neither specific nor sensitive [104, 147].

Polysomnography with EMG monitoring can be helpful in revealing PLMD and sleep disturbances.

### **Clinical course and prognostic features**

The long-term clinical outcome of neurosarcoidosis has not been thoroughly evaluated. The low prevalence of the disease makes large long-term follow-up studies difficult. Furthermore, the natural history of the disease remains unclear because of therapeutic intervention [148].

The prognosis of patients with neurosarcoidosis varies. The disease may be monophasic or self-limiting, it may come and go, or it may incessantly progress. Apparently, more than two-thirds of patients with this disease respond to treatment and, therefore, do well. In other cases, the progression may be slow and steady. Neurosarcoidosis carries a mortality of 10%, more than twice that of all other manifestations of the disease combined [149].

The course seems to depend on the type of nervous tissue involved: patients with dural lesions, peripheral neuropathy, cranial nerve lesions and, to a lesser degree, non-enhancing brain lesions seem to fare better than patients with leptomeningeal, brain parenchymal and spinal lesions [1, 14, 150]. Patients with mass lesions or hydrocephalus tend to show more relapses and are often resistant to therapy [151–153]. FERRIBY *et al.* [154] found that sarcoidosis patients with CNS involvement during the course of the disease had a higher Modified Oxford Handicap Scale score than those with peripheral nervous system involvement ( $p < 0.02$ ). Thus, CNS involvement may be a predictive factor for a less favourable disease course, and early and intensive treatment should be particularly considered in such cases [154].

There have been no controlled studies and few prospective studies of therapy in neurosarcoidosis. Evidence for improvement with treatment is anecdotally reported in many cases, but progression of the disease may occur despite therapy [14, 155–158]. Most relapses occur while tapering prednisone to  $\leq 10$  mg [153]. ALLEN *et al.* [17] found, in their prospective study of 32 patients with neurosarcoidosis, neurological improvement in 16 out of 19 (84%) of their patients after therapy and five out of 13 (38%) of the untreated patients. The most predictable response occurred in patients with peripheral neuropathy: 12 out of 14 treated patients responded. Only one out of eight patients who remained untreated improved spontaneously. ZAJICEK *et al.* [158] found progression of disease in more than half of their 47 prospectively followed neurosarcoidosis patients, despite corticosteroid and other immunosuppressive therapies.

In a retrospective study, MANZ [4] compared five cases with incidental clinically

---

unapparent sarcoidosis, six with systemic sarcoidosis without CNS involvement and four with a variety of neurological manifestations in addition to systemic sarcoidosis. They died at a mean age of 55, 47 and 38 yrs, respectively. Thus it appears that sarcoidosis in some patients may cause no or only trivial symptoms, whereas, in the other group of younger patients, it may be severe and debilitating. If the CNS involvement occurs early in the course, it pursues a rapidly progressive course with poor prognosis despite appropriate management [4].

## Therapy

### Medication

Considering the morbidity and mortality of neurosarcoidosis, most authors recommend early treatment. However, clear guidelines and indications, as well as prospective controlled studies, are not available in neurosarcoidosis, and prospective multicentric studies are warranted. As a result, recommendations about treatment are based on experience rather than evidence.

The therapeutic medical options for neurosarcoidosis are similar to those in sarcoidosis at other locations, and corticosteroids represent the drugs of first choice [159]. Doses in neurosarcoidosis are higher than those advised for the treatment of other localisations of sarcoidosis, including pulmonary. In general, the initial recommended dose is 40 mg *q.d.*, whereas, in neurosarcoidosis, an initial dose of 1 mg·kg body weight<sup>-1</sup>·day<sup>-1</sup> is usually recommended. In severe cases, high doses of intravenous methylprednisolone may be used for a few days in order to obtain a high initial loading dose. Some may use bolus pulsed methylprednisolone once a week, eventually along with low daily doses of oral prednisone, or treatment on alternate days, to avoid the side-effects associated with long-term high-dose oral treatment [158]. However, at present there is not enough evidence to recommend this. Although corticosteroids suppress inflammation in many patients, symptoms tend to recur in a subset of patients at doses of prednisone of <10–25 mg·day<sup>-1</sup>, or the equivalent in other corticoid types, making cessation of corticoids difficult. Furthermore, the incidence of steroid-related side-effects is extremely high with such prolonged treatment.

In patients in whom corticosteroids may be contraindicated, cytotoxic agents, such as methotrexate, azathioprine, ciclosporin and cyclophosphamide, have been used [157, 158, 160–162]. The choice of one or the other is more a matter of experience than of double-blind studies. On the basis of safety and efficacy, methotrexate and azathioprine may be preferred. Methotrexate has been the most widely reported drug for sarcoidosis, and its utility in sarcoidosis has been reviewed [163]. It appears to be well tolerated and associated with minimal toxic effects. The major problem is liver toxicity, for which regular blood tests are needed. The response rate of methotrexate in neurosarcoidosis is ~60%, which is similar to that in chronic sarcoidosis [161]. Azathioprine has been reported useful in chronic sarcoidosis, although others have been disappointed with its ability in treating patients with refractory sarcoidosis [164]. Treatment with ciclosporin has also resulted in variable outcomes [161]. It appears that ~75% of neurosarcoidosis patients respond to ciclosporin [157, 160]. The response rates for intravenously administered cyclophosphamide seem to be ~60–80% in patients with corticosteroid-resistant neurosarcoidosis [161, 162]. A short-course pulsed regimen appeared to minimise cumulative toxicity [162]. The place of newer immunosuppressive agents, such as mycophenolate mofetil, has yet to be determined.

Drugs that alter the immune system or block cytokine effect have also been used for

the treatment of patients with sarcoidosis. The antimalarial agents chloroquine and hydroxychloroquine have been reported useful in the treatment of some patients with neurological sarcoidosis [165]. Tumour necrosis factor (TNF) is released at higher levels by alveolar macrophages from patients with active sarcoidosis, and the levels go down with corticosteroid or methotrexate therapy [164]. These observations have led to studies that suppress TNF release or block its effect on the cell. Immunomodulators known to suppress TNF release are thalidomide and infliximab. Infliximab has been shown effective in few cases with refractory sarcoidosis. In refractory neurosarcoidosis, it may also be effective [166–170]. The toxicity of treatment for up to 1 yr is low. However, the effect of long-term treatment is still unclear [164]. An important complication associated with infliximab has been the increased rate of tuberculosis [171].

Whether or not anti-TNF- $\alpha$  therapy is beneficial in SFN related to sarcoidosis is unknown to date. However, the following case underlines this possibility. Theoretical support for the effect of anti-TNF- $\alpha$  therapy on SFN may be found in the following. First, it has been appreciated recently that pro-inflammatory cytokines, including TNF- $\alpha$ , contribute to the development of inflammatory and neuropathic pain, as well as hyperalgesia [172]. Secondly, TNF- $\alpha$  plays an important role in neuropathies such as Guillain-Barré syndrome. In Guillain-Barré syndrome, small nerve fibres are also involved. An elevated serum concentration of TNF- $\alpha$  shows a positive correlation with neuropathy severity in patients with Guillain-Barré syndrome [173, 174]. Furthermore, the decrease in serum TNF- $\alpha$  levels and increase in serum soluble TNF receptor levels show a positive correlation with neuropathy recovery following treatment in these patients. Finally, the presence of SFN in several immune-mediated diseases suggests a common final pathway in the pathogenesis of the disorder that may be related to the ongoing inflammatory process. This similarity might be related to cytokine release in immune-mediated diseases. Support for the hypothesis that SFN in immune-mediated diseases is related to cytokine release is found in pharmacological and physiological studies. These studies report that pro-inflammatory cytokines, such as TNF- $\alpha$ , are strongly involved in the generation and maintenance of neuropathic pain [172, 175–178]. Therefore, it is tempting to speculate that anti-TNF- $\alpha$  therapy might be beneficial in SFN.

Case F reveals two new and important issues. First, severe SFN appeared to be reversible in this case. Secondly, TNF- $\alpha$  may be a crucial cytokine in the pathogenesis of SFN related to sarcoidosis, and possibly in other immune-mediated inflammatory diseases, as well as in diabetes. The successful reaction to anti-TNF- $\alpha$  therapy is very promising, and this observation opens a window for new therapeutic and pathogenetic SFN studies.

In figure 6, a therapeutic flow chart for neurosarcoidosis is presented. Side-effects, as well as experience with certain drugs, may play a role in drug choice (table 6).

**Case F.** A 39-yr-old Caucasian man with known sarcoidosis for 2 yrs was diagnosed with severe SFN with autonomic involvement. Owing to his clinical deterioration, he was unable to work. Treatment with 40 mg prednisone *q.d.* was initiated, without benefit, however, and tapered. Thereafter, methotrexate was added and increased up to 20 mg weekly. Despite this, his symptoms deteriorated. Several neuropathic pain treatments initiated achieved no improvement. He developed severe skin lesions on both hands. The lesions were diagnosed as burns due to insensitivity to heat, attributable to the SFN.

Subsequently, infliximab was started at a dosage of 400 mg once every 4 weeks. This was remarkably successful; all clinical features of sarcoidosis and SFN improved. Control TTT and cardiovascular autonomic function testing both showed spectacular improvement in his SFN features. Moreover, his quality of life improved substantially and he even restarted working successfully.

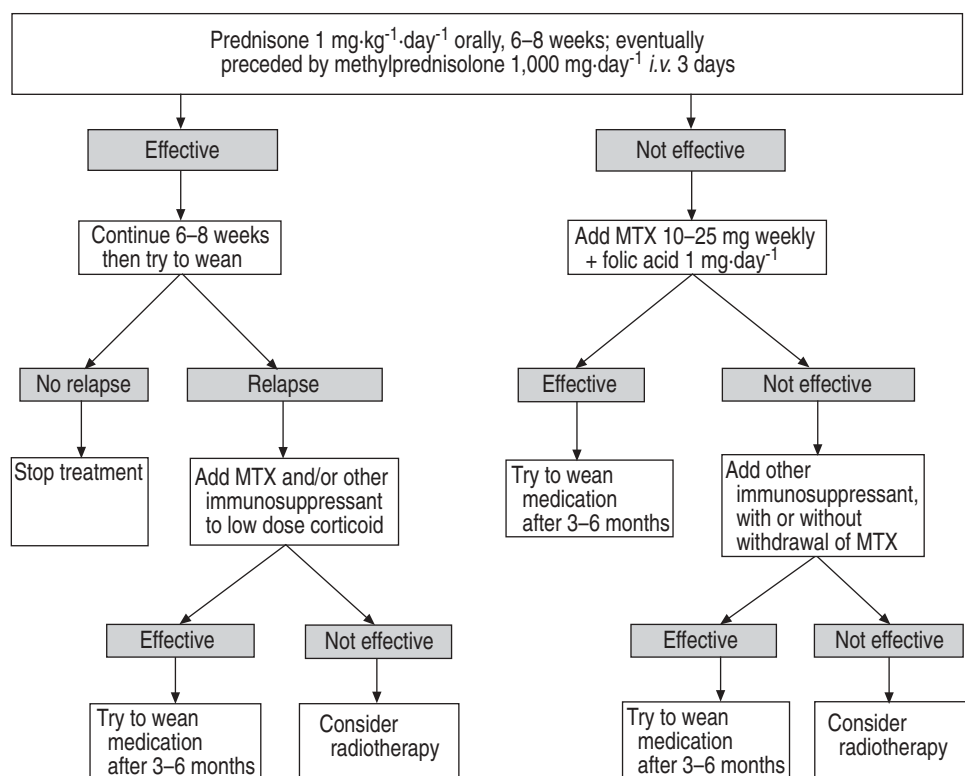


Fig. 6. – Therapeutic flow chart for patients diagnosed with neurosarcoidosis. Recommendations are based on experience rather than evidence. MTX: methotrexate.

## Radiation

There are several reports on radiation therapy in refractory neurosarcoidosis [179–183]. Although evidence-based recommendations cannot be provided, radiation therapy may be considered in patients who do not respond to medication.

## Neurosurgical treatment

Neurosurgical resection of intracranial and spinal granulomas is only indicated in life-threatening situations, or when insufficient effect is achieved with medical treatment. However, extramedullary spinal lesions may be amenable to surgical resection with post-operative steroid therapy [184]. Hydrocephalus usually requires ventriculoperitoneal shunting [185, 186].

## Conclusions

Neurosarcoidosis is a disease with many faces. Diagnosis is based on the combination of clinical and radiological evidence and histological evidence of granuloma formation. Judicious use of the recently developed CT, MRI and PET may obviate the need for

**Table 6. – Medical treatment in neurosarcoidosis**

Medication	Starting dose	Side-effects <sup>#</sup>	Remarks
Corticosteroids			
Prednisone	1 mg·kg <sup>-1</sup> ·day <sup>-1</sup> <i>p.o.</i>	Osteoporosis, Cushing's syndrome, hypertension, diabetes mellitus, ulcus pepticum, pseudotumour cerebri, glaucoma, cataract, euphoria, psychosis Very rare within 3 days	
Methylprednisolone	1000 mg·day <sup>-1</sup> <i>i.v.</i> for 3 days		
Cytotoxic agents <sup>†</sup>			
Methotrexate	10–25 mg once weekly orally or <i>s.c.</i>	Anaemia, neutropenia, hepatic dysfunction, pneumonitis	Should be combined with folic acid (1 mg·day <sup>-1</sup> <i>p.o.</i> ) Expensive Cheap Urinalysis monthly to monitor for microscopic haematuria
Ciclosporin	5 mg·kg <sup>-1</sup> ·day <sup>-1</sup> divided in 2 doses <i>p.o.</i>	Renal insufficiency, hypertension	
Azathioprine	50 mg <i>t.i.d.</i> orally	Anaemia, neutropenia, hepatic dysfunction	
Cyclophosphamide	50–200 mg <i>q.d.</i> , <i>p.o.</i> 500 mg <i>i.v.</i> once every 2–3 weeks	Cystitis, neutropenia	
Immunomodulators <sup>†</sup>			
Hydroxychloroquine	200 mg·day <sup>-1</sup> <i>p.o.</i>	Retinopathy, ototoxicity, myopathy, cardiomyopathy, neuropathy, neuropsychiatric	Routine eye examinations every 3–6 months
Infliximab	3 mg·kg <sup>-1</sup> <i>i.v.</i> once in weeks 1, 3 and 5, then once every 6 weeks	Fever, headache, dizziness, flushes, nausea, abdominal pain, dyspepsia, fatigue, myalgia, arthralgia, polyneuropathy	Tuberculosis screening is indicated before treatment is started Contraindicated in patients with heart failure Should be combined with methotrexate

<sup>#</sup>: all can cause infection due to immunosuppression; <sup>†</sup>: generally used as adjuncts to low-dose steroids, or as steroid-sparing agents when long-term treatment is necessary; in refractory patients, they may be used in combination with high-dose steroids.



biopsy in selected cases. Once the diagnosis is established, treatment choices are limited, and include corticosteroids, antimalarials and anticytotoxic agents.

### **Keynote messages**

1) Neurosarcoidosis, like a chameleon, has many faces. It can involve any part of the neurological apparatus. SFN is a recently recognised complication of sarcoidosis.

2) Histological evidence is needed to establish a firm diagnosis.

3) Corticosteroids are the drug of first choice in neurosarcoidosis. Several cytotoxic agents, including methotrexate, cyclophosphamide and azathioprine, have been used. Antimalarials have been found to be effective in selected cases. The value of new drugs that block various cytokines needs to be established.

### **Summary**

The nervous system is involved in 5–15% of patients with sarcoidosis. When present, neurosarcoidosis can be serious and devastating. The disease presents in many different ways and resembles many other neurological disorders. Thus, without biopsy evidence, the diagnosis of nervous system sarcoidosis remains a troublesome clinical dilemma. The firm diagnosis of neurosarcoidosis requires a biopsy specimen and consistent neurological presentation in a patient with multisystemic sarcoidosis. Corticosteroids represent the drug of first choice. In addition, several cytotoxic agents and antimalarial agents are used to treat sarcoidosis. The future is pregnant with expectations of new drugs that block inflammatory cytokines involved in the pathogenesis of sarcoidosis.

**Keywords:** Neurosarcoidosis, small fibre neuropathy.

### **References**

1. Stern BJ, Krumholz A, Johns C, Scott P, Nissim J. Sarcoidosis and its neurological manifestations. *Arch Neurol* 1985; 42: 909–917.
2. James DG, Sharma OP. Neurosarcoidosis. *Proc R Soc Med* 1967; 60: 1169–1170.
3. Sharma OP, Sharma AM. Sarcoidosis of the nervous system. A clinical approach. *Arch Intern Med* 1991; 151: 1317–1321.
4. Manz HJ. Pathobiology of neurosarcoidosis and clinicopathologic correlation. *Can J Neurol Sci* 1983; 10: 50–55.
5. Iwai K, Tachibana T, Takemura T, Matsui Y, Kitaichi M, Kawabata Y. Pathological studies on sarcoidosis autopsy. I. Epidemiological features of 320 cases in Japan. *Acta Pathol Jpn* 1993; 43: 372–376.
6. Burns TM. Neurosarcoidosis. *Arch Neurol* 2003; 60: 1166–1168.
7. Minagar A, Hardjasudarma M, Kelley RE. Neurosarcoidosis. *Neurology* 2002; 59: 477.
8. Oksanen V. Neurosarcoidosis. *Sarcoidosis* 1994; 11: 76–79.
9. Scott TF. Neurosarcoidosis: progress and clinical aspects. *Neurology* 1993; 43: 8–12.
10. Chan Seem CP, Spokes EG. Neurosarcoidosis. *Lancet* 1985; 2: 1363.
11. Sharma OP. Neurosarcoidosis. *Chest* 1991; 100: 301–302.

12. Strefling AM, Summerville JW, Urich H. Involvement of choroid plexuses in neurosarcoidosis. *Acta Neuropathol (Berl)* 1987; 74: 402–404.
13. Kidd D, Beynon HL. The neurological complications of systemic sarcoidosis. *Sarcoidosis Vasc Diffuse Lung Dis* 2003; 20: 85–94.
14. Oksanen V. Neurosarcoidosis: clinical presentations and course in 50 patients. *Acta Neurol Scand* 1986; 73: 283–290.
15. Pentland B, Mitchell JD, Cull RE, Ford MJ. Central nervous system sarcoidosis. *Q J Med* 1985; 56: 457–465.
16. Sharma OP, Lamb C. Cancer in interstitial pulmonary fibrosis and sarcoidosis. *Curr Opin Pulm Med* 2003; 9: 398–401.
17. Allen RK, Sellars RE, Sandstrom PA. A prospective study of 32 patients with neurosarcoidosis. *Sarcoidosis Vasc Diffuse Lung Dis* 2003; 20: 118–125.
18. Delaney P. Neurologic manifestations in sarcoidosis: review of the literature, with a report of 23 cases. *Ann Intern Med* 1977; 87: 336–345.
19. Kieff DA, Boey H, Schaefer PW, Goodman M, Joseph MP. Isolated neurosarcoidosis presenting as anosmia and visual changes. *Otolaryngol Head Neck Surg* 1997; 117: S183–S186.
20. Jennings JW, Rojiani AM, Brem SS, Murtagh FR. Necrotizing neurosarcoidosis masquerading as a left optic nerve meningioma: case report. *AJNR Am J Neuroradiol* 2002; 23: 660–662.
21. Achiron L, Strominger M, Witkin N, Primo S. Sarcoid optic neuropathy: a case report. *J Am Optom Assoc* 1995; 66: 646–651.
22. Sharma OP. Cardiac and neurologic dysfunction in sarcoidosis. *Sarcoidosis* 1997; 18: 813–825.
23. Arias M, Iglesias A, Vila O, Brasa J, Conde C. MR imaging findings of neurosarcoidosis of the gasserian ganglion: an unusual presentation. *Eur Radiol* 2002; 12: 2723–2725.
24. Oki M, Takizawa S, Ohnuki Y, Shinohara Y. MRI findings of VIIth cranial nerve involvement in sarcoidosis. *Br J Radiol* 1997; 70: 859–861.
25. Sugita M, Sano M, Uchigata M, Aruga T, Matsuoka R. Facial nerve enhancement on gadolinium-DTPA in a case with neurosarcoidosis. *Intern Med* 1997; 36: 825–828.
26. von Brevern M, Lempert T, Bronstein AM, Kocen R. Selective vestibular damage in neurosarcoidosis. *Ann Neurol* 1997; 42: 117–120.
27. Sugaya F, Shijubo N, Takahashi H, Abe S. Sudden hearing loss as the initial manifestation of neurosarcoidosis. *Sarcoidosis Vasc Diffuse Lung Dis* 1996; 13: 54–56.
28. Jardine DL, Melton IC, Bennett SI, Crozier IG, Donaldson IM, Ikram H. Baroreceptor denervation presenting as part of a vagal mononeuropathy. *Clin Auton Res* 2000; 10: 69–75.
29. Castroagudin JF, Gonzalez-Quintela A, Moldes J, Forteza J, Barrio E. Acute reversible dysphagia and dysphonia as initial manifestations of sarcoidosis. *Hepatogastroenterology* 1999; 46: 2414–2418.
30. Jaffe R, Bogomolski-Yahalom V, Kramer MR. Vocal cord paralysis as the presenting symptom of sarcoidosis. *Respir Med* 1994; 88: 633–636.
31. Colover J. Sarcoidosis with involvement of the nervous system. *Brain* 1948; 71: 451–475.
32. Blain JG, Riley W, Logothetis J. Optic nerve manifestations of sarcoidosis. *Arch Neurol* 1965; 13: 307–309.
33. Wachtel AS, Saunders M. Optic nerve sarcoidosis. *Mayo Clin Proc* 1997; 72: 791.
34. Kumar N, Frohman EM. Spinal neurosarcoidosis mimicking an idiopathic inflammatory demyelinating syndrome. *Arch Neurol* 2004; 61: 586–589.
35. Graham EM, Ellis CJ, Sanders MD, McDonald WI. Optic neuropathy in sarcoidosis. *J Neurol Neurosurg Psychiatry* 1986; 49: 756–763.
36. Gelwan MJ, Kellen RI, Burde RM, Kupersmith MJ. Sarcoidosis of the anterior visual pathway: successes and failures. *J Neurol Neurosurg Psychiatry* 1988; 51: 1473–1480.
37. Bandyopadhyay T, Das D, Das SK, Ghosh A. A case of neurosarcoidosis presenting with multiple cranial nerve palsy. *J Assoc Physicians India* 2003; 51: 328–329.
38. Palacios E, Rigby PL, Smith DL. Cranial neuropathy in neurosarcoidosis. *Ear Nose Throat J* 2003; 82: 251–252.

39. De Broff B, Donahue S. Bilateral optic neuropathy as the initial manifestation of systemic sarcoidosis. *Am J Ophthalmol* 1993; 116: 108–111.
40. James DG, Zatzouff MA, Trowell J, Rose FC. Papilloedema in sarcoidosis. *Br J Ophthalmol* 1967; 51: 526–529.
41. Karma A. Ocular sarcoidosis. *Semin Respir Med* 1992; 131: 425–431.
42. Westlake J, Heath JD, Spalton DJ. Sarcoidosis involving the optic nerve and hypothalamus. *Arch Ophthalmol* 1995; 113: 669–670.
43. Plotkin GR, Patel BR. Neurosarcoidosis presenting as chronic lymphocytic meningitis. *Pa Med* 1986; 89: 36–37.
44. Powers WJ, Miller FM. Sarcoidosis mimicking glioma: case report and review of intracranial sarcoidosis like mass lesions. *Neurology* 1981; 31: 907–910.
45. Mayer SA, Yim GK, Onesti ST, Lynch T, Faust PL, Marder K. Biopsy-proven isolated sarcoid meningitis. Case report. *J Neurosurg* 1993; 78: 994–996.
46. Jensen S, Jensen IW. Bilateral papilledema with normal CT-scan in neurosarcoidosis. *Acta Med Scand* 1987; 222: 381–383.
47. Willigers H, Koehler PJ. Amnesic syndrome caused by neurosarcoidosis. *Clin Neurol Neurosurg* 1993; 95: 131–135.
48. Kumpe DA, Rao CV, Garcia JH, Heck AF. Intracranial neurosarcoidosis. *J Comput Assist Tomogr* 1979; 3: 324–330.
49. Cahill DW, Salzman M. Neurosarcoidosis: a review of the rarer manifestations. *Surg Neurol* 1981; 15: 204–211.
50. Akhondi H, Barochia S, Holmstrom B, Williams MJ. Hydrocephalus as a presenting manifestation of neurosarcoidosis. *South Med J* 2003; 96: 403–406.
51. Maniker AH, Cho ES, Schulder M. Neurosarcoid infiltration of the ventricular catheter causing shunt failure: a case report. *Surg Neurol* 1997; 48: 527–529.
52. Veres L, Utz JP, Houser OW. Sarcoidosis presenting as a central nervous system mass lesion. *Chest* 1997; 111: 518–521.
53. Nowak DA, Widenka DC. Neurosarcoidosis: a review of its intracranial manifestation. *J Neurol* 2001; 248: 363–372.
54. Stubgen JP. Neurosarcoidosis presenting as a retroclival mass. *Surg Neurol* 1995; 43: 85–87; discussion 87–88.
55. Gizzi MS, Lidov M, Rosenbaum D. Neurosarcoidosis presenting as a tumour of the basal ganglia and brainstem: sequential MRI. *Neurol Res* 1993; 15: 93–96.
56. Randeva HS, Davison R, Chamoun V, Bouloux PM. Isolated neurosarcoidosis – a diagnostic enigma: case report and discussion. *Endocrine* 2002; 17: 241–247.
57. Murialdo G, Tamagno G. Endocrine aspects of neurosarcoidosis. *J Endocrinol Invest* 2002; 25: 650–662.
58. Gleckman AM, Patalas ED, Joseph JT. Sudden unexpected death resulting from hypothalamic sarcoidosis. *Am J Forensic Med Pathol* 2002; 23: 48–51.
59. Tamagno G, Murialdo G. Amenorrhea–galactorrhea syndrome as an uncommon manifestation of isolated neurosarcoidosis. *Ann Ital Med Int* 2001; 16: 260–266.
60. Sato N, Sze G, Kim JH. Cystic pituitary mass in neurosarcoidosis. *AJNR Am J Neuroradiol* 1997; 18: 1182–1185.
61. Konrad D, Gartenmann M, Martin E, Schoenle EJ. Central diabetes insipidus as the first manifestation of neurosarcoidosis in a 10-year-old girl. *Horm Res* 2000; 54: 98–100.
62. Bullmann C, Faust M, Hoffmann A, et al. Five cases with central diabetes insipidus and hypogonadism as first presentation of neurosarcoidosis. *Eur J Endocrinol* 2000; 142: 365–372.
63. Guoth MS, Kim J, de Lotbiniere AC, Brines ML. Neurosarcoidosis presenting as hypopituitarism and a cystic pituitary mass. *Am J Med Sci* 1998; 315: 220–224.
64. Ahmadi J, Meyers GS, Segall HD, Sharma OP, Hinton DR. Lymphocytic adenohypophysitis: contrast-enhanced MR imaging in five cases. *Radiology* 1995; 195: 30–34.

65. Urich H. Neurosarcoidosis or granulomatous angiitis: a problem of definition. *Mt Sinai J Med* 1977; 44: 718–725.
66. Friedman SH, Gould DJ. Neurosarcoidosis presenting as psychosis and dementia: a case report. *Int J Psychiatry Med* 2002; 32: 401–403.
67. Popli AP. Risperidone for the treatment of psychosis associated with neurosarcoidosis. *J Clin Psychopharmacol* 1997; 17: 132–133.
68. Bona JR, Fackler SM, Fendley MJ, Nemeroff CB. Neurosarcoidosis as a cause of refractory psychosis: a complicated case report. *Am J Psychiatry* 1998; 155: 1106–1108.
69. Sabaawi M, Gutierrez-Nunez J, Fragala MR. Neurosarcoidosis presenting as schizophreniform disorder. *Int J Psychiatry Med* 1992; 22: 269–274.
70. Caplan L, Corbett J, Goodwin J, Thomas C, Shenker D, Schatz N. Neuro-ophthalmologic signs in the angiitic form of neurosarcoidosis. *Neurology* 1983; 33: 1130–1135.
71. Akova YA, Kansu T, Duman S. Pseudotumor cerebri secondary to dural sinus thrombosis in neurosarcoidosis. *J Clin Neuroophthalmol* 1993; 13: 188–189.
72. Redwood MD, Winer JB, Rossor M. Neurosarcoidosis presenting as benign intracranial hypertension. *Eur Neurol* 1990; 30: 282–283.
73. Krumholz A, Stern BJ, Stern EG. Clinical implications of seizures in neurosarcoidosis. *Arch Neurol* 1991; 48: 842–844.
74. Kanjwal Y, Kosinski D, Grubb BP. The postural orthostatic tachycardia syndrome: definitions, diagnosis, and management. *Pacing Clin Electrophysiol* 2003; 26: 1747–1757.
75. Junger SS, Stern BJ, Levine SR, Sipos E, Marti-Masso JF. Intramedullary spinal sarcoidosis: clinical and magnetic resonance imaging characteristics. *Neurology* 1993; 43: 333–337.
76. Day AL, Sybert GW. Spinal cord sarcoidosis. *Ann Neurol* 1977; 1: 79–85.
77. Vinas FC, Rengachary S, Kupsky WJ. Spinal cord sarcoidosis: a diagnostic dilemma. *Neurol Res* 2001; 23: 347–352.
78. Rieger J, Hosten N. Spinal cord sarcoidosis. *Neuroradiology* 1994; 36: 627–628.
79. Sauter MK, Panitch HS, Kristt DA. Myelopathic neurosarcoidosis: diagnostic value of enhanced MRI. *Neurology* 1991; 41: 150–151.
80. Castellano-Sanchez AA. Extensive leptomeningeal and intraparenchymatous spinal cord neurosarcoidosis. *South Med J* 2000; 93: 815–817.
81. Hayat GR, Walton TP, Smith KR Jr, Martin DS, Manepalli AN. Solitary intramedullary neurosarcoidosis: role of MRI in early detection. *J Neuroimaging* 2001; 11: 66–70.
82. Sakaibara R, Uchiyama T, Kuwabara S, et al. Autonomic dysreflexia due to neurogenic bladder dysfunction; an unusual presentation of spinal cord sarcoidosis. *J Neurol Neurosurg Psychiatry* 2001; 71: 819–820.
83. Prelog K, Blome S, Dennis C. Neurosarcoidosis of the conus medullaris and cauda equina. *Australas Radiol* 2003; 47: 295–297.
84. Shah JR, Lewis RA. Sarcoidosis of the cauda equina mimicking Guillain-Barre syndrome. *J Neurol Sci* 2003; 208: 113–117.
85. Abrey LE, Rosenblum MK, DeAngelis LM. Sarcoidosis of the cauda equina mimicking leptomeningeal malignancy. *J Neurooncol* 1998; 39: 261–265.
86. Ku A, Lachmann E, Tunkel R, Nagler W. Neurosarcoidosis of the conus medullaris and cauda equina presenting as paraparesis: case report and literature review. *Paraplegia* 1996; 34: 116–120.
87. Verma KK, Forman AD, Fuller GN, Dimachkie MM, Vriesendorp FJ. Cauda equina syndrome as the isolated presentation of sarcoidosis. *J Neurology* 2000; 247: 573–574.
88. Fitzpatrick KJ, Chancellor MB, Rivas DA, Kumon H, Mandel S, Manon-Espaillet R. Urologic manifestation of spinal cord sarcoidosis. *J Spinal Cord Med* 1996; 19: 201–203.
89. Gainsborough N, Hall SM, Hughes RA, Leibowitz S. Sarcoid neuropathy. *J Neurol* 1991; 238: 177–180.
90. Miller R, Sheron N, Semple S. Sarcoidosis presenting with an acute Guillain-Barre syndrome. *Postgrad Med J* 1989; 65: 765–767.

91. Strickland-Marmol LB, Fessler RG, Rojiani AM. Necrotizing sarcoid granulomatosis mimicking an intracranial neoplasm: clinicopathologic features and review of the literature. *Mod Pathol* 2000; 13: 909–913.
92. Oh SJ. Sarcoid polyneuropathy: a histologically proved case. *Ann Neurol* 1980; 7: 178–181.
93. Said G, Lacroix C, Plante-Bordeneuve V, *et al.* Nerve granulomas and vasculitis in sarcoid peripheral neuropathy: a clinicopathological study of 11 patients. *Brain* 2002; 125: 264–275.
94. Nemni R, Galassi G, Cohen M, *et al.* Symmetric sarcoid polyneuropathy: analysis of a sural nerve biopsy. *Neurology* 1981; 31: 1217–1223.
95. Vital C, Aubertin J, Ragnault JM, Amigues H, Mouton L, Bellance R. Sarcoidosis of the peripheral nerve: a histological and ultrastructural study of two cases. *Acta Neuropathol (Berl)* 1982; 58: 111–114.
96. Challenor YB, Felton CP, Brust JC. Peripheral nerve involvement in sarcoidosis: an electrodiagnostic study. *J Neurol Neurosurg Psychiatry* 1984; 47: 1219–1222.
97. Galassi G, Gibertoni M, Mancini A, *et al.* Sarcoidosis of the peripheral nerve: clinical, electrophysiological and histological study of two cases. *Eur Neurol* 1984; 23: 459–465.
98. Elkin R, Willcox PA. Neurosarcoidosis. A report of 5 cases. *S Afr Med J* 1985; 67: 943–946.
99. Baron B, Goldberg AL, Rothfus WE, Sherman RL. CT features of sarcoid infiltration of a lumbosacral nerve root. *J Comput Assist Tomogr* 1989; 13: 364–365.
100. Matthews WB. Sarcoid neuropathy. In: Dyck PJ, Thomas PK, Lambert EH, Bunge R, eds. *Peripheral Neuropathy*. 2nd Edn. Philadelphia, PA, W.B. Saunders, 1984, pp. 2018–2026.
101. Scott TS, Brillman J, Gross JA. Sarcoidosis of the peripheral nervous system. *Neurol Res* 1993; 15: 389–390.
102. Koffman B, Junck L, Elias SB, Feit HW, Levine SR. Polyradiculopathy in sarcoidosis. *Muscle Nerve* 1999; 22: 608–613.
103. Hoitsma E, Marziniak M, Faber CG, *et al.* Small fiber neuropathy in sarcoidosis. *Lancet* 2002; 359: 2085–2086.
104. Hoitsma E, Drent M, Verstraete E, *et al.* Abnormal warm and cold sensation thresholds suggestive of small-fibre neuropathy in sarcoidosis. *Clin Neurophysiol* 2003; 114: 2326–2333.
105. Hoitsma E, Reulen JP, de Baets M, Drent M, Spaans F, Faber CG. Small fiber neuropathy: a common and important clinical disorder. *J Neurol Sci* 2004; 227: 119–130.
106. Hoitsma E, Faber CG, van Kroonenburgh MJPG, *et al.* Association of small fiber neuropathy with cardiac sympathetic dysfunction in sarcoidosis. *Sarcoidosis, Vasc Diffuse Lung Dis* 2005; 22: 43–50.
107. Polydefkis M, Allen RP, Hauer P, Earley CJ, Griffin JW, McArthur JC. Subclinical sensory neuropathy in late-onset restless legs syndrome. *Neurology* 2000; 55: 1115–1121.
108. Verbraecken J, Hoitsma E, van der Grinten CP, Cobben NA, Wouters EF, Drent M. Sleep disturbances associated with periodic leg movements in chronic sarcoidosis. *Sarcoidosis Vasc Diffuse Lung Dis* 2004; 21: 137–146.
109. Hoitsma E, Faber CG, Drent M, Sharma OP. Neurosarcoidosis: a clinical dilemma. *Lancet Neurol* 2004; 3: 397–407.
110. Woolf CJ, Mannion RJ. Neuropathic pain: aetiology, symptoms, mechanisms, and management. *Lancet* 1999; 353: 1959–1964.
111. Sindrup SH, Jensen TS. Efficacy of pharmacological treatments of neuropathic pain: an update and effect related to mechanism of drug action. *Pain* 1999; 83: 389–400.
112. Mendell JR, Sahenk Z. Clinical practice. Painful sensory neuropathy. *N Engl J Med* 2003; 348: 1243–1255.
113. Alpert JN, Groff AE, Bastion FO, Blum MA. Acute polymyositis caused by sarcoidosis, report of a case and review of the literature. *Mt Sinai J Med* 1979; 46: 486–488.
114. Stjernberg N, Cajander S, Truedsson H, Uddenfeldt P. Muscle involvement in sarcoidosis. *Acta Med Scand* 1981; 209: 212–216.
115. Silverstein A, Siltzbach LE. Muscle involvement in sarcoidosis. Asymptomatic, myositis, and myopathy. *Arch Neurol* 1969; 21: 235–241.

116. Jamal MM, Cilursu AM, Hoffman EL. Sarcoidosis presenting as acute myositis. Report and review of the literature. *J Rheumatol* 1988; 15: 1868–1871.
117. Nidiry JJ, Mines S, Hackney R, Nabhani H. Sarcoidosis: a unique presentation of dysphagia, myopathy, and photophobia. *Am J Gastroenterol* 1991; 86: 1679–1682.
118. Fonseca GA, Baca S, Altman RD. Acute myositis and dermatitis as the initial presentation of sarcoidosis. *Clin Exp Rheumatol* 1993; 11: 553–556.
119. Lynch JP 3rd. Neurosarcoidosis: how good are the diagnostic tests? *J Neuroophthalmol* 2003; 23: 187–189.
120. Moore FG, Andermann F, Richardson J, Tampieri D, Giaccone R. The role of MRI and nerve root biopsy in the diagnosis of neurosarcoidosis. *Can J Neurol Sci* 2001; 28: 349–353.
121. Uchino M, Nagao T, Harada N, Shibata I, Hamatani S, Mutou H. Neurosarcoidosis without systemic sarcoidosis – case report. *Neurol Med Chir (Tokyo)* 2001; 41: 48–51.
122. Cipri S, Gambardella G, Campolo C, Mannino R, Consoli D. Unusual clinical presentation of cerebral-isolated sarcoidosis. Case report and review of the literature. *J Neurosurg Sci* 2000; 44: 140–144.
123. Israel HL, Albertine KH, Park CH, Patrick H. Whole-body gallium 67 scans. Role in diagnosis of sarcoidosis. *Am Rev Respir Dis* 1991; 144: 1182–1186.
124. Jarman PR, Whyte MK, Glass DM, Peters AM. Case report: imaging of central nervous system sarcoidosis with gallium-67 single photon emission computed tomography. *Br J Radiol* 1996; 69: 192–194.
125. Dubey N, Miletich RS, Wasay M, Mechtler LL, Bakshi R. Role of fluorodeoxyglucose positron emission tomography in the diagnosis of neurosarcoidosis. *J Neurol Sci* 2002; 205: 77–81.
126. Tuisku IS, Kontinen YT, Soinila S, Karma A, Tervo TM. Neurosarcoidosis mimicking Sjogren's syndrome. *Acta Ophthalmol Scand* 2004; 82: 599–602.
127. Liu DT, Lee VY, Tam PM, Chan WM. Ophthalmology for diagnosis of sarcoidosis. *Lancet Neurol* 2004; 3: 578.
128. Spaide RF, Ward DL. Conjunctival biopsy in the diagnosis of sarcoidosis. *Br J Ophthalmol* 1990; 74: 469–471.
129. Williams JW. The identification of sarcoid granulomas in the nervous system. *Proc Roy Soc Med* 1967; 60: 38–40.
130. Davis LE, Kornfeld M. Neurocysticercosis: neurologic, pathogenetic, diagnostic and therapeutic aspects. *Eur Neurol* 1991; 31: 229–240.
131. Pickuth D, Spielmann RP, Heywang-Kobrunner SH. Role of radiology in the diagnosis of neurosarcoidosis. *Eur Radiol* 2000; 10: 941–944.
132. Fels C, Riegel A, Javaheripour-Otto K, Obenauer S. Neurosarcoidosis: findings in MRI. *Clin Imaging* 2004; 28: 166–169.
133. Tahmouh AJ, Amir MS, Connor WW, *et al.* CSF-ACE activity in probable CNS neurosarcoidosis. *Sarcoidosis Vasc Diffuse Lung Dis* 2002; 19: 191–197.
134. Oksanen V, Fyhrquist F, Somer H, Gronhagen-Riska C. Angiotensin converting enzyme in cerebrospinal fluid: a new assay. *Neurology* 1985; 35: 1220–1223.
135. Jones DB, Mitchell D, Horn DB, Edwards CR. Cerebrospinal fluid angiotensin converting enzyme levels in the diagnosis of neurosarcoidosis. *Scott Med J* 1991; 36: 144–145.
136. Rubinstein I, Hoffstein V. Angiotensin-converting enzyme in neurosarcoidosis. *Arch Neurol* 1987; 44: 249–250.
137. Oksanen V, Fyhrquist F, Gronhagen-Riska C, Somer H. CSF angiotensin-converting enzyme in neurosarcoidosis. *Lancet* 1985; 1: 1050–1051.
138. Chan Seem CP, Norfolk G, Spokes EG. CSF angiotensin-converting enzyme in neurosarcoidosis. *Lancet* 1985; 1: 456–457.
139. Schweisfurth H, Schiöberg-Schiegnitz S, Kuhn W, Parusel B. Angiotensin I converting enzyme in cerebrospinal fluid of patients with neurological diseases. *Klin Wochenschr* 1987; 65: 955–958.
140. Borucki SJ, Nguyen BV, Ladoulis CT, McKendall RR. Cerebrospinal fluid immunoglobulin abnormalities in neurosarcoidosis. *Arch Neurol* 1989; 46: 270–273.

141. McLean BN, Mitchell DN, Thompson EJ. Local synthesis of specific IgG in the cerebrospinal fluid of patients with neurosarcoidosis detected by antigen immunoblotting using Kveim material. *J Neurol Sci* 1990; 99: 165–175.
142. Scott TF, Seay AR, Goust JM. Pattern and concentration of IgG in cerebrospinal fluid in neurosarcoidosis. *Neurology* 1989; 39: 1637–1639.
143. Juozevicius JL, Rynes RI. Increased helper/suppressor T-lymphocyte ratio in the cerebrospinal fluid of a patient with neurosarcoidosis. *Ann Intern Med* 1986; 104: 807–808.
144. Oksanen V, Gronhagen-Riska C, Tikanoja S, Somer H, Fyhrquist F. Cerebrospinal fluid lysozyme and  $\beta_2$ -microglobulin in neurosarcoidosis. *J Neurol Sci* 1986; 73: 79–87.
145. Oksanen V. New cerebrospinal fluid, neurophysiological and neuroradiological examinations in the diagnosis and follow-up of neurosarcoidosis. *Sarcoidosis* 1987; 4: 105–110.
146. Stewart JD, Low PA, Fealey RD. Distal small fiber neuropathy: results of tests of sweating and autonomic cardiovascular reflexes. *Muscle Nerve* 1992; 15: 661–665.
147. Lacomis D. Small-fiber neuropathy. *Muscle Nerve* 2002; 26: 173–188.
148. Wells CE. The natural history of neurosarcoidosis. *Proc R Soc Med* 1967; 60: 1172–1174.
149. James DG. Life-threatening situations in sarcoidosis. *Sarcoidosis Vasc Diffuse Lung Dis* 1998; 15: 134–139.
150. Christoforidis GA, Spickler EM, Recio MV, Mehta BM. MR of CNS sarcoidosis: correlation of imaging features to clinical symptoms and response to treatment. *Am J Neuroradiol* 1999; 20: 655–669.
151. Walker A, Tyor W. Neurosarcoidosis. *Curr Treat Options Neurol* 2001; 3: 529–535.
152. Schlitt M, Duvall ER, Bonnin J, Morawetz RB. Neurosarcoidosis causing ventricular loculation, hydrocephalus, and death. *Surg Neurol* 1986; 26: 67–71.
153. Luke RA, Stern BJ, Krumholz A, Johns CJ. Neurosarcoidosis: the long-term clinical course. *Neurology* 1987; 37: 461–463.
154. Ferriby D, de Seze J, Stojkovic T, *et al.* Long-term follow-up of neurosarcoidosis. *Neurology* 2001; 57: 927–929.
155. Heck AW, Phillips LH 2nd. Sarcoidosis and the nervous system. *Neurol Clin* 1989; 7: 641–654.
156. Michotte A, Dequenne P, Jacobovitz D, Hildebrand J. Focal neurological deficit with sudden onset as the first manifestation of sarcoidosis: a case report with MRI follow-up. *Eur Neurol* 1991; 31: 376–379.
157. Agbogu BN, Stern BJ, Sewell C, Yang G. Therapeutic considerations in patients with refractory neurosarcoidosis. *Arch Neurol* 1995; 52: 875–879.
158. Zajicek JP, Scolding NJ, Foster O, *et al.* Central nervous system sarcoidosis – diagnosis and management. *QJM* 1999; 92: 103–117.
159. Selroos O. Treatment of sarcoidosis. *Sarcoidosis* 1994; 11: 80–83.
160. Stern BJ, Schonfeld SA, Sewell C, Krumholz A, Scott P, Belendiuk G. The treatment of neurosarcoidosis with cyclosporine. *Arch Neurol* 1992; 49: 1065–1072.
161. Lower EE, Broderick JP, Brott TG, Baughman RP. Diagnosis and management of neurological sarcoidosis. *Arch Intern Med* 1997; 157: 1864–1868.
162. Doty JD, Mazur JE, Judson MA. Treatment of corticosteroid-resistant neurosarcoidosis with a short-course cyclophosphamide regimen. *Chest* 2003; 124: 2023–2026.
163. Baughman RP, Lower EE. A clinical approach to the use of methotrexate for sarcoidosis. *Thorax* 1999; 54: 742–746.
164. Hunninghake GW, Costabel U, Ando M, *et al.* American Thoracic Society/European Respiratory Society/World Association of Sarcoidosis and Other Granulomatous Disorders: statement on sarcoidosis. *Sarcoidosis Vasc Diffuse Lung Dis* 1999; 16: 149–173.
165. Sharma OP. Effectiveness of chloroquine and hydroxychloroquine in treating selected patients with sarcoidosis with neurological involvement. *Arch Neurol* 1998; 55: 1248–1254.
166. Pettersen JA, Zochodne DW, Bell RB, Martin L, Hill MD. Refractory neurosarcoidosis responding to infliximab. *Neurology* 2002; 59: 1660–1661.

167. Carter JD, Valeriano J, Vasey FB, Bognar B. Refractory neurosarcoidosis: a dramatic response to infliximab. *Am J Med* 2004; 117: 277–279.
168. Sollberger M, Fluri F, Baumann T, *et al.* Successful treatment of steroid-refractory neurosarcoidosis with infliximab. *J Neurol* 2004; 251: 760–761.
169. Katz JM, Bruno MK, Winterkorn JM, Nealon N. The pathogenesis and treatment of optic disc swelling in neurosarcoidosis: a unique therapeutic response to infliximab. *Arch Neurol* 2003; 60: 426–430.
170. Morcos Z. Refractory neurosarcoidosis responding to infliximab. *Neurology* 2003; 60: 1220–1221.
171. Keane J, Gershon S, Wise RP, *et al.* Tuberculosis associated with infliximab, a tumor necrosis factor  $\alpha$ -neutralizing agent. *N Engl J Med* 2001; 345: 1098–1104.
172. Oprea A, Kress M. Involvement of the proinflammatory cytokines tumor necrosis factor- $\alpha$ , IL-1 $\beta$ , and IL-6 but not IL-8 in the development of heat hyperalgesia: effects on heat-evoked calcitonin gene-related peptide release from rat skin. *J Neurosci* 2000; 20: 6289–6293.
173. Radhakrishnan VV, Sumi MG, Reuben S, Mathai A, Nair MD. Serum tumour necrosis factor- $\alpha$  and soluble tumour necrosis factor receptors levels in patients with Guillain-Barre syndrome. *Acta Neurol Scand* 2004; 109: 71–74.
174. Creange A, Belec L, Clair B, Raphael JC, Gherardi RK. Circulating tumor necrosis factor (TNF)- $\alpha$  and soluble TNF- $\alpha$  receptors in patients with Guillain-Barre syndrome. *J Neuroimmunol* 1996; 68: 95–99.
175. Sommer C, Marziniak M, Myers RR. The effect of thalidomide treatment on vascular pathology and hyperalgesia caused by chronic constriction injury of rat nerve. *Pain* 1998; 74: 83–91.
176. Schafers M, Geis C, Brors D, Yaksh TL, Sommer C. Anterograde transport of tumor necrosis factor- $\alpha$  in the intact and injured rat sciatic nerve. *J Neurosci* 2002; 22: 536–545.
177. Empl M, Renaud S, Erne B, *et al.* TNF- $\alpha$  expression in painful and nonpainful neuropathies. *Neurology* 2001; 56: 1371–1377.
178. Cunha FQ, Poole S, Lorenzetti BB, Ferreira SH. The pivotal role of tumour necrosis factor  $\alpha$  in the development of inflammatory hyperalgesia. *Br J Pharmacol* 1992; 107: 660–664.
179. Menninger MD, Amdur RJ, Marcus RB Jr. Role of radiotherapy in the treatment of neurosarcoidosis. *Am J Clin Oncol* 2003; 26: E115–E118.
180. Kang S, Suh JH. Radiation therapy for neurosarcoidosis: report of three cases from a single institution. *Radiat Oncol Investig* 1999; 7: 309–312.
181. Rubinstein I, Gray TA, Moldofsky H, Hoffstein V. Neurosarcoidosis associated with hypersomnolence treated with corticosteroids and brain irradiation. *Chest* 1988; 94: 205–206.
182. Bejar JM, Kerby GR, Ziegler DK, Festoff BW. Treatment of central nervous system sarcoidosis with radiotherapy. *Ann Neurol* 1985; 18: 258–260.
183. Bruns F, Pruemer B, Haverkamp U, Fischeidick AR. Neurosarcoidosis: an unusual indication for radiotherapy. *Br J Radiol* 2004; 77: 777–779.
184. Fried ED, Landau AJ, Sher JH, Rao C. Spinal cord sarcoidosis: a case report and review of the literature. *J Assoc Acad Minor Phys* 1993; 4: 132–137.
185. Hesselmann V, Wedekind C, Terstegge K, *et al.* An isolated fourth ventricle in neurosarcoidosis: MRI findings. *Eur Radiol* 2002; 12: Suppl. 3, S1–S3.
186. Foley KT, Howell JD, Junck L. Progression of hydrocephalus during corticosteroid therapy for neurosarcoidosis. *Postgrad Med J* 1989; 65: 481–484.