

Case Report

Carcinoid Tumor of Lung with Cushing's Syndrome

Manouchehr Aghajanzadeh MD*, Ali Alavy MD**, Saba Hoda MD***,
Fereshteh Mohammadi MD†

Carcinoid tumor of lung with Cushing's syndrome is a rare condition. We report a 38-year-old man, with a 28-month history of Cushing's syndrome presented with hypertension, diabetes mellitus, decreased libido, muscle weakness and fatigability, moon facies, buffalo hump, truncal obesity, cutaneous striae, and easy bruisability. Diagnosis was made by measurements of ACTH (149 pg/mL) and cortisol levels (36 µg/dL) and computerized tomography of the chest.

Archives of Iranian Medicine, Volume 10, Number 1, 2007: 94 – 96.

Keywords: Carcinoid tumor • Cushing's syndrome • neuroendocrine tumor

Introduction

Bronchopulmonary carcinoid (BPC) tumors arise from the neuroendocrine Kulchitsky cells located in the bronchial epithelium and comprise between 2% and 5% of all primary lung cancers.¹⁻³ BPC tumors represent a spectrum of neuroendocrine neoplasms ranging from the highly fatal small-cell lung cancer to the very favorable typical carcinoid tumor.^{4,5} BPC tumors have been associated with a variety of endocrine disorders including Cushing's syndrome (CS), which is caused by ectopic adrenocorticotrophic hormone (ACTH) secretion.⁶ Some authors consider ACTH-secreting BPC to be a substantially more aggressive subtype of BPC tumors.^{1,5} However, the influence of CS on prognosis is not well established. Herein, we present a case of BPC tumor with CS.

Case Report

A 38-year-old man presented with adiposity of the face, neck, and trunk, hypertension, hyperpigmentation, impotence, diabetes mellitus, purple

striae, and muscular weakness since 28 months ago.

Laboratory findings showed a high blood sugar (FBS: 155 mg/dL). The level of plasma cortisol was 36 (normal range: 5.5 – 23) µg/dL. Dexamethason suppression test was abnormal. Urine cortisol and ACTH levels were 400 (normal range: 26 – 134) µg/dL/24 h and 149 (normal range: 13.6 – 65) pg/mL, respectively. Other laboratory findings were normal.

Ultrasonography of the kidneys and computerized tomography (CT) scan of the brain were unremarkable. Chest X-ray showed a lesion in the right lung; CT scan of the chest revealed a 2.2-cm nodule in the right upper lobe (Figure 1).

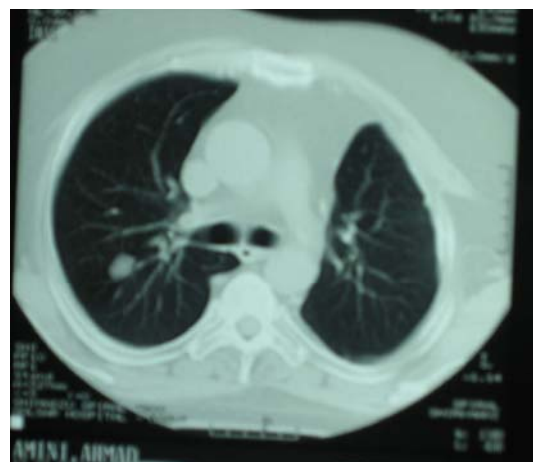


Figure 1. Computerized tomography of the chest with a nodule in the right upper lobe.

Authors' affiliations: *Department of Thoracic Surgery, **Department of Pulmonary Medicine, ***Department of Pathology, †Department of Endocrinology, Guilan University of Medical Science, Rasht, Iran.

Corresponding author and reprints: Manouchehr Aghajanzadeh MD, Golsar St., 100 Ave., No. 37, Rasht, Iran. Tel: +98-131-772-2389, Fax: +98-131-772-2389, E-mail: Maghajanazadeh2003@yahoo.com.

Accepted for publication: 15 February 2006

Bronchoscopy was normal. The patient, then, underwent surgery. Thoracotomy and right upper lobectomy were performed. Histopathologic examination revealed a small creamy nodule 1.3 cm in diameter in the lumen of the bronchus. On microscopic examination, it composed of nests of uniform tumoral cells arranged in an organized pattern and separated by fine fibrovascular stroma. The tumor extended throughout the bronchial wall. Immunohistochemical staining for synaptophysin, chromogranin, and ACTH were positive (Figure 2). Seven hours after the operation, the blood pressure fell down and the patient developed tachycardia and shock. The hypotension was treated with intravenous administration of hydrocortison. Because of adrenal gland suppression, the patient was given 10 mg prednisolon daily. One month after surgery, ACTH level was 16 pg/mL and cortisol level was 10 mg/dL. After three months, the patient had no symptoms and signs.

Discussion

CS secondary to BPC is rare and accounts for approximately 1% of all patients diagnosed with this syndrome.^{1, 4, 7}

BPC tumors are, however, the most frequent cause of CS resulting from ectopic ACTH secretion.^{7, 8} In 1990, Pass et al published the National Institutes of Health experience pertaining to this condition. Their study described 14 patients and represented the largest single institution operative experience at that time.⁶ Thirteen of

those patients exhibited BPC and one had thymic carcinoid. Seven patients had mediastinal lymph node metastasis and six underwent adjuvant radiation therapy. Both BPC and CS recurred in two patients. The mean follow-up period was 21 months. At that time, twelve patients were still alive and ten were symptom-free.⁶

A more recent report by Shrager and colleagues from the Massachusetts General Hospital found lymph node metastasis in four out of seven patients; three were diagnosed with N2 disease.⁵ In those seven patients, the primary pulmonary resection was lobectomy in three and wedge excision in two patients. CS recurred in one (14%) of the seven patients.^{2, 4}

Because of the high incidence of mediastinal lymph node metastases and increased BPC recurrence rate, these authors concluded that ACTH-secreting BPC is a more aggressive variant of typical carcinoid.^{6, 9} In contrast, in a new report, patients had a lower incidence of lymph node metastases (32%) and, with a median of 6.5 years of follow-up, the rate of recurrence of BPC was 17%. Only 10% of the patients exhibited N2 disease.¹ ACTH-secreting BPC is a rare but distinct clinical entity and its diagnosis is almost always delayed.¹

Long duration of symptoms in CS, before surgical resection, is common. This is likely attributed to several factors including the rarity of the condition, the paucity of pulmonary symptoms, and the difficulty in diagnosis.¹ This is in contrast to the presentation of the majority of hormonally quiescent BPC symptoms, which often includes wheezing, cough, and hemoptysis.^{4, 10, 11} BPC with CS rarely occurs with pulmonary symptoms.¹ As in our case, the patient did not have any pulmonary complaints. Moreover, CS resulting from ectopic ACTH-secreting tumors may be biochemically indistinguishable from the pituitary-dependent CS, which makes the diagnosis more difficult.⁶⁻⁸ The introduction of inferior petrosal sinus sampling for corticotropin, however, has definitely helped to ascertain the diagnosis.¹ Patients with an ectopic source of ACTH exhibit no gradient between the pituitary and peripheral samples, as compared to patients with an ACTH-secreting pituitary tumor where petrosal vein levels exceed peripheral ACTH levels.⁶⁻⁸ CT scan of chest should be considered for all patients with corticotropin-dependent CS.^{6, 8, 12} The CT scan identified a small tumor in our patient, whereas chest radiography did not identify the tumor. Anatomic resection and

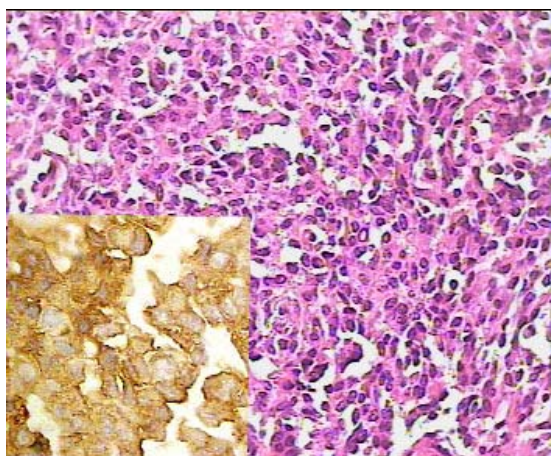


Figure 2. Photomicrograph showing tumoral cells with uniform nuclei. The cells were arranged in nests. Immunohistochemical stain showing positive reaction for synaptophysin.

complete mediastinal lymphadenectomy a choice for BPC and have low recurrence rate, but recurrence was more common after segmental resection.¹ Prognosis after pulmonary resection for these patients is excellent.¹ In our patient, we performed right upper lobectomy without mediastinal lymphadenectomy that resulted in improvement of the patient.

Acknowledgment

We thank Gilda Aghajanzadeh and Naematolla Khatmi for revision and final editing of this manuscript.

References

- 1 Deb SJ, Nichols FC, Allen MS, Deschamps C, Cassivi SD, Pairolero PC. Pulmonary carcinoid tumors with Cushing's syndrome: an aggressive variant or not? *Ann Thorac Surg.* 2005; **79**: 1132 – 1136.
- 2 Mineo TC, Guggino G, Mineo D, Vanni G, Ambrogi V. Relevance of lymph node micrometastases in radically resected endobronchial carcinoid tumors. *Ann Thorac Surg.* 2005; **80**: 428 – 432.
- 3 Ginsberg RJ. Carcinoid tumors. In: Shield TW, Lo Cicero J, Ponn RB, eds. *General Thoracic Surgery*. 5th ed. Philadelphia: Lipincott, Williams and Wilkins; 2004: 1493 – 1504.
- 4 Harpole DH Jr, Feldman JM, Buchanan S, Young WG, Wolfe WG. Bronchial carcinoid tumors: a retrospective analysis of 126 patients. *Ann Thorac Surg.* 1992; **54**: 50 – 54.
- 5 Shrager JB, Wright CD, Wain JC, Torchiana DF, Grillo HC, Mathisen DJ. Bronchopulmonary carcinoid tumors associated with Cushing's syndrome: a more aggressive variant of typical carcinoid. *J Thorac Cardiovasc Surg.* 1997; **114**: 367 – 375.
- 6 Pass HI, Doppman JL, Nieman L, Stovroff M, Vetto J, Norton JA, et al. Management of the ectopic ACTH syndrome due to thoracic carcinoids. *Ann Thorac Surg.* 1990; **50**: 52 – 57.
- 7 Limper AH, Carpenter PC, Scheithauer B, Staats BA. The Cushing syndrome induced by bronchial carcinoid tumors. *Ann Intern Med.* 1992; **117**: 209 – 214.
- 8 Leinung MC, Young WF Jr, Whitaker MD, Scheithauer BW, Trastek VF, Kivols LK. Diagnosis of corticotropin-producing bronchial carcinoid tumors causing Cushing's syndrome. *Mayo Clin Proc.* 1990; **65**: 1314 – 1321.
- 9 Garcia-Yuste M, Matilla JM, Alvarez-Gago T, Duque JL, Heras F, Cerezal LJ, et al. Prognostic factors in neuroendocrine lung tumors: a Spanish Multicenter Study. Spanish Multicenter Study of Neuroendocrine Tumors of the Lung of the Spanish Society of Pneumology and Thoracic Surgery (EMETNE-SEPAR). *Ann Thorac Surg.* 2000; **70**: 258 – 263.
- 10 Horton KM, Fishman EK. Cushing syndrome due to a pulmonary carcinoid tumor: multimodality imaging and diagnosis. *J Comput Assist Tomogr.* 1998; **22**: 804 – 806.